

Results of endoscopic endonasal dacryocystorhinostomy: A prospective cohort study

Ayesha Jawad,¹ Ayisha Kausar,² Saira Iftikhar,³ Nadia Akhtar,⁴ Zafar Rabbani⁵

Abstract

Objective: To evaluate the success rate of endoscopic endonasal dacryocystorhinostomy.

Method: The prospective cohort study was conducted at the Ophthalmology and Otorhinolaryngology departments, Shifa Foundation Community Health Centre, Islamabad, Pakistan, from October 2017 to September 2019, and comprised chronic dacryocystitis patients who underwent endoscopic endonasal dacryocystorhinostomy. Endoscopic dacryocystorhinostomy with or without lacrimal intubation was performed under general anaesthesia. The patients were followed up post-operative at 1 week, 1 month, 6 months and 12 months. Data was analysed using SPSS 20.

Results: Of the 47 patients, 41(87.2%) were females. The overall mean age was 40.70±10.84 years (range: 25-66 years). Lacrimal intubation was performed in 31(66%) patients. Surgical success was achieved in 46(97.9%) patients. Of them, 37(78.7%) patients were completely symptom-free, while 9(19.1%) were partially symptomatic and were managed conservatively. Treatment failure requiring repeat surgical procedure was the case with 1(2.1%) patient. Procedure failure was more likely in patients with previous attacks of acute dacryocystitis (p=0.003).

Conclusion: Endoscopic dacryocystorhinostomy was found to be a safe procedure with good anatomical and functional outcomes in chronic dacryocystitis patients.

Keywords: Chronic dacryocystitis, Dacryocystorhinostomy, DCR, Epiphora, Endoscopic endonasal, Intubation.

(JPMA 71: 1420; 2021) DOI: <https://doi.org/10.47391/JPMA.187>

Introduction

Dacryocystorhinostomy (DCR) is the treatment of choice in the management of nasolacrimal duct (NLD) obstruction in adult patients.^{1,2} The obstruction is bypassed by creating an opening between the medial wall of the lacrimal sac and the lateral wall of the middle meatus of the nasal cavity. The procedure, first explained in early 20th century, has undergone many modifications since then, and the technique has changed in almost a century from external DCR to non-endoscopic endonasal surgery and then to modern-day endoscopic endonasal DCR.³

Different techniques have been employed to improve surgical success rates of DCR, including intraoperative application of mitomycin-C,⁴ intubation of lacrimal passages^{5,6} and post-operative topical drugs, including steroids and leukotriene antagonists⁷ etc.

Although initially the success percentage for conventional external approach DCR was superior to endonasal techniques, advancements in surgical

equipment and more meticulous surgical techniques have led to comparable success rates of endonasal non-endoscopic and endoscopic DCRs.^{8,9} Endoscopic DCR is cosmetically more acceptable with no surface scar having less risks of bleeding, giving early post-operative recovery and being a safer procedure in terms of preserving the lacrimal pump mechanism.¹⁰ It is now considered an alternative to external DCR in both adult and paediatric patients.^{11,12}

The current study was conducted to investigate the results and success rate of endoscopic endonasal DCR in patients with epiphora secondary to chronic dacryocystitis.

Patients and Methods

The prospective cohort study was conducted from October 2017 to September 2019 at the Ophthalmology and Otorhinolaryngology departments of Shifa Foundation Community Health Centre, Islamabad, Pakistan. After approval by the institutional ethics review committee, the sample size was calculated using a formula in line with literature.¹³ As no recent or old local epidemiological study was found related to the incidence of acquired NLD obstruction, the prevalence was taken as 3.1%, which was the average of two studies reporting adult chronic dacryocystitis (0.79%),¹⁴ and paediatric NLD obstruction (5.8%).¹⁵ Confidence interval (CI) was kept at

.....
^{1,3,5}Department of ENT, ²Department of Ophthalmology, Shifa College of Medicine, Shifa Tameer e Millat University, Islamabad, ⁴Department of Ophthalmology, Federal Medical Dental College, Federal General Hospital, Islamabad, Pakistan.

Correspondence: Ayisha Kausar. Email: drayisha_79@hotmail.com

95%, alpha value at 0.05, standard normal variate at 1.96, and absolute precision was at 0.05.

The sample was raised as non-probability convenience sampling technique from among subjects visiting the out-patient departments (OPDs). Those included were patients aged >16 years who were scheduled for endoscopic DCR surgery for chronic dacryocystitis. Those with previous history of intranasal surgery, history of unsuccessful external DCR on the affected side, inflammatory diseases of the conjunctiva that predispose to epiphora, chronic sinusitis and secondary nasolacrimal passage obstruction due to nasal trauma or maxillectomy etc. were excluded.

After taking written informed consent, demographic and clinical data were collected using a specially-designed proforma. History of acute dacryocystitis and any previous probing and syringing was noted. A detailed nasal and ophthalmic examination was performed. Preoperative clinical features, like mucocele, deviated nasal septum, epiphora, purulent discharge, patency status of lacrimal puncta on slit lamp biomicroscope and findings on regurgitation test, were documented.

Endoscopic endonasal DCR was performed under general anaesthesia. All surgeries were performed by experienced ear, nose, throat (ENT) surgeons with surgical experience of >5 years. Preoperative 1ml lidocaine with epinephrine was injected in the axilla of the middle meatus, and nasal packs with adrenaline 1:100,000 were applied for 5 minutes. A rigid nasal endoscope was used. Incision was made at the anterior aspect of frontal process, 2 horizontal and 1 vertical, with blade size 15, and the lacrimal bone was exposed after elevating the mucoperiosteal flap. Kerrison punches 45°, 90° were used for bone-cutting. The lacrimal sac was exposed and a window was made in the medial aspect. Lacrimal puncta dilation and syringing was performed. The decision for lacrimal intubation was made depending on the surgeons' preferences, difficulty in dissection, adhesions and the size of the ostium. Polyfax eye ointment was applied at the local site at the completion of the procedure.

Post-operative treatment regimen included oral antibiotics, oral antihistamines and non-steroidal anti-inflammatory drugs (NSAIDs) for one week, steroid antibiotic eye drops tobramycin + dexamethasone 4 times a day and nasal moisturizers / emollients for 2 weeks.

The follow-up was planned at post-operative 1 week, 1 month, 6 months and 12 months with documentation of

epiphora, purulent discharge, need for syringing, nasal adhesions on rigid endoscopy, etc. Patients who failed to maintain follow-up were contacted through telephone and were asked about the presence of symptoms, like epiphora or discharge etc. Nasal endoscopy was performed post-operatively in all patients. Lacrimal tubes were endoscopically removed after 6 months in all except one patient in whom it was accidentally pulled out by the patient who then cut the tube at home. Surgical procedure was categorised as successful when patients were totally asymptomatic till the last follow-up. Partial success was considered if they had few or negligible symptoms but were satisfied by the surgical outcome. Procedure failure was indicated by purulent discharge, persisting symptoms or post-surgery recurrence.

Data was analysed using SPSS 20. Mean \pm standard deviation (SD) were calculated for quantitative variables, like age, while frequency and percentages were worked out for qualitative variables, like gender. Pearson's chi square test was used to see the effect of various demographic and clinical parameters on surgical success rate. $P < 0.05$ was taken as significant.

Results

Of the 47 patients, 41 (87.2%) were females. The overall mean age was 40.70 ± 10.84 years (range: 25-66 years). Lacrimal intubation was performed in 31 (66%) patients. The mean follow-up duration was 14.53 ± 3.0 months (range: 12-24 months). All patients presented with a history of epiphora. Majority of patients 39 (83.0%) had

Table: Demographics and pre-operative clinical parameters and their relationship with surgical outcome.

Clinical Features	N = 47 (%)	P value
Age in years		
21-30	9.1 (19.1%)	
31-40	18 (38.3%)	
41-50	12 (25.5%)	0.879
51-60	7 (14.9%)	
> 60 years.	1 (2.1%)	
Gender		
Female	41 (87%)	0.911
Male	6 (13%)	
Laterality		0.572
Right	24 (51%)	
Left	23 (49%)	
Epiphora	47 (100%)	Not Applicable
History of acute Dacryocystitis	8 (17.0%)	0.003
Mucocele	5 (10.6%)	0.941
Positive Regurgitation test	45 (95.7%)	0.754
History of probing & syringing	11 (23.4%)	0.513
Deviated nasal septum	3 (6.4%)	0.096

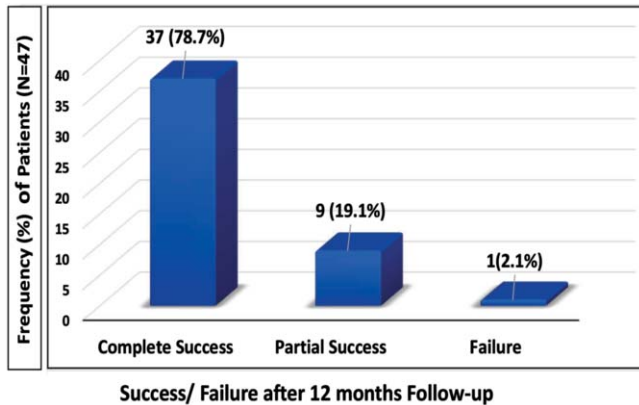


Figure-1: Surgical outcome of Endoscopic Dacryocystorhinostomy.

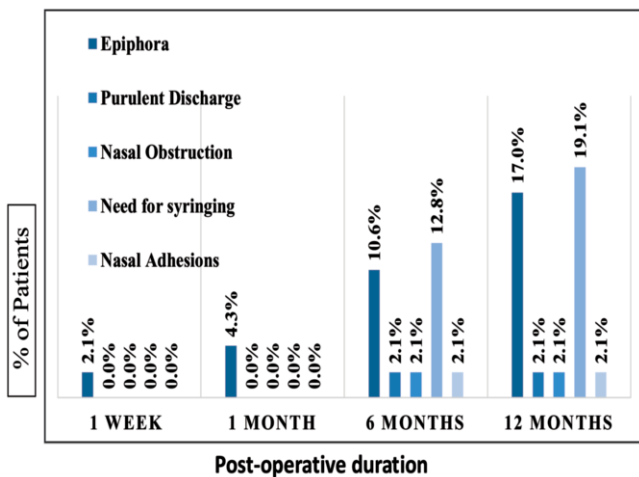


Figure-2: Post-operative clinical parameters.

chronic dacryocystitis with no complaints of acute exacerbations. Regurgitation test was positive in 45(95.7%) patients. Overall, 5(10.6%) had a lacrimal sac mucocele, and 3(6.4%) had a deviated nasal septum which required surgical intervention in the same setting. History of probing and syringing was found in 11(23.4%) patients. (Table-I).

Surgical success was achieved in 46(97.9%) patients. Of them, 37(78.7%) patients were completely symptom-free, while 9(19.1%) were partially symptomatic and were managed conservatively. Treatment failure requiring repeat surgical procedure was the case with 1(2.1%) patient (Figure-1).

Majority of patients 30(64%) were aged 31-50 years, while 1(2.1%) patient was aged >60 years. There was no significant difference in surgical failure amongst various age groups (p=0.087). The only patient with complete treatment failure was in the 41-50 years age bracket. Procedure failure was more likely in patients with

previous attacks of acute dacryocystitis (p=0.003), while the rest of the risk factors were not significantly associated with poor surgical outcome (p>0.05).

The effect of intubation on surgical outcome was not significant (p=0.190).

During follow-up, only one (2.1%) patient had mild turbinate hypertrophy on endoscopy at 6 months (Figure-2).

Discussion

A large number of patients in oculoplastic clinics present with complaints of epiphora or excessive tearing. Underlying aetiology for epiphora can be multifactorial. Acquired NLD obstruction is reported as a common cause for epiphora¹⁶. DCR is the treatment of choice for managing acquired NLD obstructions.^{1,2} Epiphora was the common presenting feature in all patients in the current study. In addition, DCR indications, like mucocele and acute chronic dacryocystitis, were similar to earlier findings by Zaman et al.¹⁷

Endoscopic DCR gives added benefit of treating associated nasal pathology in the same setting and hence improving the surgical success rate. Three patients (6.4%) in the current study had deviated nasal septum and underwent simultaneous septoplasty. All three had complete relief of epiphora till 1-year follow-up. A study also reported septoplasty / additional nasal procedure in 5.55% of their patients undergoing endo DCR.¹⁸

Several local and international have shown a gender predilection for epiphora and NLD obstruction. It is more common in females than males.¹⁹ Majority of patients (87%) in the current study were also females. Similar gender and age groups have been reported by two other local studies,^{20,21} while one study⁴ reported a relatively higher number of male patients.

The current study found no significant association of lacrimal intubation with anatomical and functional success after endoscopic DCR. According to some studies, stenting has a limited role in increasing surgical success rate and there is evidence of comparable results without intubation.^{12,20} Others have given importance to intubation.^{4,21} A recent meta-analysis reported that lacrimal stenting by silicone tubing improved success rates, specifically in patients undergoing external DCR, while it was not always the case with endo DCR.²² The meta-analysis, however, reported its limitation for not being able to give a concluding decision after statistical power and trial sequential analysis.

The overall success rate in the current study was

46(97.9%). Currently, the reported success rates of endo DCR in literature are >90%.^{20,21,23,24}

Epiphora and lacrimal passages disorders should be evaluated by ophthalmologists and otorhinolaryngologists.²⁵ A joint lacrimal clinic may help in facilitating such patients and reducing individual follow-up to either ophthalmologist or otorhinolaryngologist.

Conclusion

Endoscopic DRC is a safe and successful technique for managing acquired NLD disorders and chronic dacryocystitis. Team work between ophthalmologists and otorhinolaryngologists has the potential to improve surgical outcomes.

Disclaimer: None.

Conflict of Interest: None.

Source of Funding: None.

References

- Grob SR, Campbell A, Lefebvre DR, Yoon MK. External Versus Endoscopic Endonasal Dacryocystorhinostomy. *Int Ophthalmol Clin* 2015;55:51-62. doi: 10.1097/IIO.0000000000000083.
- Kamal S, Ali MJ, Nair AG. Outcomes of endoscopic dacryocystorhinostomy: Experience of a fellowship trainee at a tertiary care center. *Indian J Ophthalmol* 2016;64:648-53. doi: 10.4103/0301-4738.194340.
- Amadi AJ. Endoscopic DCR vs External DCR: What's Best in the Acute Setting? *J Ophthalmic Vis Res* 2017;12:251-3. doi: 10.4103/jovr.jovr_133_17.
- Mukhtar SA, Jamil AZ, Ali Z. Efficacy of external dacryocystorhinostomy (DCR) with and without mitomycin-C in chronic dacryocystitis. *J Coll Physicians Surg Pak* 2014;24:732-5. doi: 10.2014/JCPSP.732735.
- Shinder R, Wu A, Mehendale RA, Tang SX, Nasser QJ, Chou E, et al. Lacrimal intubation during dacryocystorhinostomy utilizing the STENTube. *Orbit* 2017;36:6-12. doi: 10.1080/01676830.2017.1279642.
- Sen P, Jain E, Mohan A, Kumar A. Surgical Outcome of External Dacryocystorhinostomy With Silicone Intubation for Recurrent Lacrimal Abscess in Children Younger Than 6 Years. *J Pediatr Ophthalmol Strabismus* 2019;56:188-93. doi: 10.3928/01913913-20190228-01.
- Yelverton JC, Holmes TW, Johnson CM, Gelves CR, Kountakis SE. Effectiveness of leukotriene receptor antagonism in the postoperative management of chronic rhinosinusitis. *Int Forum Allergy Rhinol* 2016;6:243-7. doi: 10.1002/alr.21649.
- Jain S, Ganguly A, Singh S, Mohapatra S, Tripathy D, Rath S. Primary Nonendoscopic Endonasal Versus Delayed External Dacryocystorhinostomy in Acute Dacryocystitis. *Ophthalmic Plast Reconstr Surg* 2017;33:285-8. doi: 10.1097/IOP.0000000000000759.
- Huang J, Malek J, Chin D, Snidvongs K, Wilcsek G, Sacks R, et al. Systematic review and meta-analysis on outcomes for endoscopic versus external dacryocystorhinostomy. *Orbit* 2014;33:81-90. doi: 10.3109/01676830.2013.842253.
- Lee JJ, Lee HM, Lim HB, Seo SW, Ahn HB, Lee SB. Learning Curve for Endoscopic Endonasal Dacryocystorhinostomy. *Korean J Ophthalmol* 2017;31:299-305. doi: 10.3341/kjo.2016.0081.
- Saniasiaya J, Abdullah B, Husain S, Wang Y, Wan Mohammad Z. Primary endoscopic endonasal dacryocystorhinostomy for pediatric nasolacrimal duct obstruction: A systematic review. *Am J Rhinol Allergy* 2017;31:328-33. doi: 10.2500/ajra.2017.31.4464.
- Marcet MM, Kuk AK, Phelps PO. Evidence-based review of surgical practices in endoscopic endonasal dacryocystorhinostomy for primary acquired nasolacrimal duct obstruction and other new indications. *Curr Opin Ophthalmol* 2014;25:443-8. doi: 10.1097/ICU.0000000000000084.
- Charan J, Biswas T. How to calculate sample size for different study designs in medical research? *Indian J Psychol Med* 2013;35:121-6. doi: 10.4103/0253-7176.116232.
- Bharadwaj M, Singh LK, Dutt B. A hospital based eye health survey to see the pattern of eye diseases in Uttarakhand, India. *Int J Res Med Sci* 2017;5:548-50.
- Farrukh S, Latif MA, Klasra AH, Ali M. Pattern of Pediatric Eye Diseases. *Pak J Ophthalmol* 2015;31:147-50.
- Ohtomo K, Ueta T. Factors Associated with the Efficacy of Probing for Adult Patients With Lacrimal Duct Obstruction. *Ophthalmic Plast Reconstr Surg* 2017;33:136-8. doi: 10.1097/IOP.0000000000000682.
- Zaman M, Babar TF, Saeed N. A review of 120 cases of dacryocystorhinostomies (Dupuy Dutemps and Bourguet technique). *J Ayub Med Coll Abbottabad* 2003;15:10-2.
- Raghuwanshi SK, Raghuwanshi S, Agarwal M, Batni G. Primary Endonasal DCR Without Stent: Our Experience and Case Series Analysis. *Indian J Otolaryngol Head Neck Surg* 2015;67:271-4. doi: 10.1007/s12070-015-0867-y.
- Shams PN, Chen PG, Wormald PJ, Sloan B, Wilcsek G, McNab A, et al. Management of functional epiphora in patients with an anatomically patent dacryocystorhinostomy. *JAMA Ophthalmol* 2014;132:1127-32. doi: 10.1001/jamaophthalmol.2014.1093.
- Ayoob M, Mahida K, Ul-Ain Q, Dawood Z. Outcome and Complications of Endoscopic Dacryocystorhinostomy without Stenting. *Pak J Med Sci* 2013;29:1236-9. doi: 10.12669/pjms.295.3393.
- Aslam MA, Mirza AB, Butt IA. Results of endoscopic endonasal dacryocystorhinostomy. *J Pak Med Assoc* 2014;64:619-23.
- Xie C, Zhang L, Liu Y, Ma H, Li S. Comparing the Success Rate of Dacryocystorhinostomy With and Without Silicone Intubation: A Trial Sequential Analysis of Randomized Control Trials. *Sci Rep* 2017;7:1936. doi: 10.1038/s41598-017-02070-y.
- Keren S, Abergel A, Manor A, Rosenblatt A, Koenigstein D, Leibovitch I, et al. Endoscopic dacryocystorhinostomy: reasons for failure. *Eye (Lond)* 2020;34:948-53. doi: 10.1038/s41433-019-0612-y.
- Ali MJ, Psaltis AJ, Murphy J, Wormald PJ. Powered endoscopic dacryocystorhinostomy: a decade of experience. *Ophthalmic Plast Reconstr Surg* 2015;31:219-21. doi: 10.1097/IOP.0000000000000261
- Penttilä E, Smirnov G, Tuomilehto H, Kaarniranta K, Seppä J. Endoscopic dacryocystorhinostomy as treatment for lower lacrimal pathway obstructions in adults: Review article. *Allergy Rhinol (Providence)* 2015;6:12-9. doi: 10.2500/ar.2015.6.0116.