

Upper gastrointestinal bleed in a toddler — an unusual encounter revealing foreign body ingestion

Rahim Ahmed,¹ Humaira Jurair,² Kamran Sadiq,³ Qalab-e-Abbas,⁴ Anwar ul Haque⁵

Abstract

Foreign body (FB) ingestion is common in children; however, management varies based on the object ingested, its location and clinical presentation. Urgent intervention is needed if any warning signs are present.

We describe the case of a four-year-old child who presented with acute onset of life-threatening upper gastro intestinal bleeding. He had no other significant previous or present complaint, and results of lab workup were inconclusive. Endoscopic evaluation revealed a sharp and hard object which was removed. Post-operative period, duration of hospitalization and subsequent follow up were uneventful.

Through this report, we wish to draw the attention of healthcare providers to the dangerous effects of FB ingestion and also emphasise that FB ingestion should be considered in differential diagnosis when unexplained upper GI haemorrhage symptoms occur acutely.

Keywords: Upper gastrointestinal bleed, Foreign body ingestion, Paediatrics.

DOI: <https://doi.org/10.47391/JPMA.03-301>

Case Report

A four-year-old male child presented in the Emergency Department (ED) of Aga Khan University Hospital, Karachi, in May 2016.

The child had acute complaints of bloody vomiting for the past six hours. Vomiting was sudden in onset, and occurred three to four times, consisting of fresh blood, with volume around 50 to 60 ml, without any cough or pain. Also there was no history of fever, bruising, petechiae or oozing from any other site.

Physical examination revealed an active alert child, in no acute distress. Vitals included temperature of 99° F, pulse rate 112 beats/min, respiratory rate of 32 breaths/minutes, oxygen saturation of 98% at room air

.....
¹⁻⁴Department of Paediatrics and Child Health, Aga Khan University Hospital, Karachi, ⁵Department of Paediatrics and Child Health, The Indus Hospital network, Karachi, Pakistan.

Correspondence: Humaira Jurair. Email: humaira.jurair@aku.edu

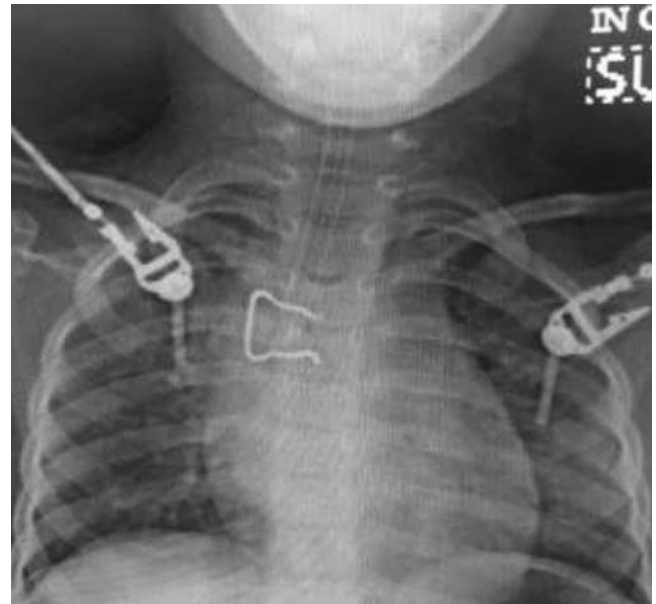


Figure-1: Radiograph of chest showing a curved metallic via endoscopy.

and blood pressure of 92/56 mm of Hg. He had obvious pallor; however, there was no sign of bleeding from any other orifice, no petechiae, bruise, etc. Oral cavity, abdominal, chest, CVS and CNS examinations were normal. There was no significant medical history, the patient had previously been well with no significant past history of gastritis, weight loss, jaundice, etc. There was also no family history of bleeding disorder or any other significant disease.

After initial stabilisation in the ED, blood work up was done which showed haemoglobin of 5 g/dl, white cell count of 9.2×10^9 per litre (N:67.1%, L:23%) and platelets at $302 \times 10^9/L$. Coagulation study, biochemistry, LFTs and ultrasound of the liver were normal.

In the ED, the child was managed with normal saline boluses and intravenous Omeprazole. Blood products were arranged. During the stay, the child had another episode of haematemesis, due to which paediatric gastroenterology consultant was called and the child was rushed to the operation room (OR) for emergency diagnostic and therapeutic workup.

In the OR, upper gastrointestinal (GI) endoscopy was



Figure-2: Metallic object extracted from the oesophagus.

attempted. The stomach was found to be filled with fresh blood. On suspicion of the presence of a hard object in upper oesophagus further study was abandoned and an immediate CXR was ordered. CXR showed a hard object lying in the oesophagus. Rigid oesophagoscopy was performed to remove the object along with flexible oesophagoscopy and to identify any bleeder. (Figures-1 & 2). Due to high risk location of the object the surgical team was taken on board to deal with any unwanted complications.

Post procedure, the patient was intubated and shifted to the intensive care unit. The child was kept nil per oral intake for 24 hours with intravenous fluid supplementation, antibiotic coverage and injection Omeprazole. No signs of further bleeding were noted. CT of the chest was planned after 24 hours to look for mediastinitis which was normal. The child remained haemodynamically stable, and was extubated after 36 hours and later shifted to the ward. Feeding was started and later progressed with no complications.

On further probing for history, the parents revealed that the object that was found was the curtain's hanging hook at their home. Nobody had witnessed the child ingesting it. The child was playing in the room with his sibling where curtains with these hooks were hanging. The child was found vomiting blood in this very room. None of the parent or any elder was present in that room, so they did not suspect it.

The child was discharged after 48 hours. The patient's

parents were counselled and altered for being more watchful and observant in future with regards to young children's care. GI endoscopic study was repeated to assess for any oesophageal tear after one week, which was normal.

Informed written consent was obtained from the patient's parent for reporting the case.

Discussion

Foreign Body ingestion is a common cause of Emergency Department (ED) visits in paediatric population, with peak prevalence between ages of six months and six years.¹⁻³ Majority of the FB pass spontaneously, but serious complications such as oesophageal abrasion, laceration, bleeding, complete oesophageal obstruction, bowel perforation and occasionally airway obstruction can occur.^{1,4} FB ingestion is a common clinical problem in Pakistan. However, only a few cases have been reported.^{5,6}

A vast majority of FB ingestions in children are accidental and involve common objects found in the home environment, such as coins, toys, jewellery, magnets, batteries and a variety of sharp objects.^{1,7} Zhao-Shen Li from China has described various cases of FB ingestion in upper-GI tract.³ In the United States and Europe, coins are the most common ingested foreign body. In the Asian community, fish bone represents a significant component of FB ingestion in both children and adults.^{1,2}

Clinical symptoms can vary with some children being completely asymptomatic. Retrospective review revealed that 50 percent of children with confirmed foreign body ingestions are asymptomatic.⁴ Symptomatic children may present with stridor, pain, drooling, dysphagia and, occasionally, airway obstruction and respiratory distress.¹ Although serious complications of FB ingestion are not very common, they have been reported, especially with batteries, magnets, hard and sharp objects and include oesophageal obstruction, erosion, perforation, upper GI bleeding, aorto-oesophageal fistula, parapharyngeal or retropharyngeal abscess and cardiopulmonary complications.⁴

Literature search reveals that sharp foreign bodies increase the complication rate from less than 1% to 15% to 35%.¹ Mortality rates have been extremely low.⁷ Simic et al reported a child's death secondary to foreign body ingestion leading to fatal upper GI haemorrhage in their report.⁸ A compilation of multiple studies, including two large series, reported no deaths in 852 adults and one death in 2,206 children. Early recognition and appropriate management is, therefore, very important.

Problem in suitable timely management can arise if FB ingestion is un-witnessed. An estimated 40 percent of

foreign body ingestions in children are not witnessed and hence the diagnosis of an ingested FB is often overlooked.⁹ The patient in our case had the same scenario; he presented with upper gastrointestinal bleeding and his parents were not with him when he swallowed the hook. High index of suspicion and the identification of unique patterns of symptoms related to FB ingestion is valuable for early diagnosis and to assure a prompt medical reaction.

For initial workup in patients with suspected FB ingestion plain radiographs are indicated; however, in one study of 325 children, only 64 cases of ingested objects were found to be radiopaque.⁴ Other tests like computed tomography, ultrasound, barium oesophagography or endoscopic examination might need to be considered in different circumstances where diagnosis of FB ingestion is entertained.⁹ Identification of the type and shape of the ingested FB with imaging or/and other techniques is imperative as management protocols are specific for objects such as coins, button batteries, small toys, pins, etc.¹⁰

Majority of swallowed objects pass through gastrointestinal tract without any problem and are eliminated in the stool.³ Objects lodged in the oesophagus, such as high-powered magnet or batteries, or sharp-pointed objects, causing oesophageal obstruction and signs of airway compromise, however, represent medical emergency and need quick endoscopic removal or surgical intervention.¹ Endoscopic retrieval of these sharp objects is accomplished; however, protecting the airway during removal is important.^{1,7} American Society for Gastrointestinal Endoscopy suggests that 10% to 20% of foreign bodies may need to be removed endoscopically.³ Webb reported 98.8% success rate of endoscopic removal of foreign bodies and 1.2% failure rate, while success rate for endoscopic foreign-body removal in a study by Zhao-Shen Li was 94.1%.³ Surgery remains the last alternative required in some cases due to location of the foreign body or due to actual or anticipated complications.^{1,4} Surgical removal is also considered for blunt objects beyond the stomach that remain in the same location for more than one week. According to literature, 80% to 90% of the foreign bodies that come to medical attention pass spontaneously, 10% to 20% require endoscopic removal, and less than 1% require surgical intervention.^{3,7}

Conclusion

We feel that FB ingestion should be considered in cases of unexplained upper GI haemorrhage, in order to intervene quickly and thus prevent irreversible complication and

consequences. Better community education, parent teaching programmes and increased awareness regarding such an event among caretakers might be of some value. Primary preventive measures that need to be considered to avoid accidental FB ingestions is keeping younger children under complete, vigilant supervision by adults at all times. Also age-appropriate safety tips should be taught by the child's physician to parents with every clinical encounter.

Strength in approach to this case: Quick intervention and timely involvement of all multidisciplinary teams required to manage the case like gastroenterologist, paediatric surgery and paediatric intensive care teams.

Limitation in approach to this case: We did not use printed resources like leaflets or booklet with age-appropriate safety tips which is a more superior approach for parents' education.

Disclaimer: None

Sources of Funding: None

Conflict of Interest: None

ERC Approval: 4747-Ped-ERC-17.

References

1. Kay M, Wyllie R. Paediatric foreign bodies and their management. *Curr Gastroenterol Rep.* 2005; 7:212-8.
2. Wong KK, Fang CX, Tam PK. Selective upper endoscopy for foreign body ingestion in children: an evaluation of management protocol after 282 cases. *J Pediatr Surg.* 2006; 41:2016-8.
3. Li ZS, Sun ZX, Zou DW, Xu GM, Wu RP, Liao Z. Endoscopic management of foreign bodies in the upper-GI tract: experience with 1088 cases in China. *Gastrointest Endosc.* 2006; 64:485-92.
4. Venkataraghavan K, Anantharaj A, Praveen P, Rani SP, Krishnan BM. Accidental ingestion of foreign object: Systematic review, recommendations and report of a case. *Saudi Dent J.* 2011; 23:177-81.
5. Samad L, Ali M, Ramzi H. Button battery ingestion: hazards of oesophageal impaction. *J Pediatr Surg.* 1999; 34:1527-31.
6. Ashraf O, Arshad M, Afzal A. Approach to foreign body ingestion, method determines outcome. *Afr Health Sci.* 2006; 6:191.
7. Aydogdu S, Arikan C, Cakir M, Baran M, Yuksekkaya HA, Saz UE, et al. Foreign body ingestion in Turkish children. *Turk J Paediatr.* 2009; 51:127-32.
8. Simic MA, Budakov BM. Fatal upper oesophageal haemorrhage caused by a previously ingested chicken bone: case report. *Am J Forensic Med Pathol.* 1998; 19:166-8.
9. Vijaysadan V, Perez M, Kuo D. Revisiting swallowed troubles: intestinal complications caused by two magnets--a case report, review and proposed revision to the algorithm for the management of foreign body ingestion. *J Am Board Fam Med.* 2006; 19:511-6.
10. Dahshan A. Management of ingested foreign bodies in children. *J Okla State Med Assoc.* 2001; 94:183-6