

## Clinical analysis of 125I seed implantation combined with Apatinib in the treatment of locally advanced lung cancer: A case series

Yiling Feng<sup>1</sup>, Bo Yang<sup>2</sup>, Xiaoping Li<sup>3</sup>

### Abstract

This clinical analysis of 125I seed implantation combined with Apatinib in the treatment of locally advanced lung cancer with negative driving genes was retrospectively performed on 19 patients in the Department of Thoracic Surgery, Tianjin First Central Hospital, from January 2018 to May 2019. Twelve cases were treated with Apatinib after 125I implantation, while the other seven were treated with 125I implantation only. IL-2R, IL-6 and TNF- $\alpha$  before and after the treatment, imaging changes every two months and related side effects were recorded. After the treatment, IL-2R, IL-6 and TNF- $\alpha$  of all the patients decreased in the first month, which was more obvious in combined therapy patients; the total effective rate in combined therapy patients was significantly higher than the others. There were no fatal complications, and all the side-effects were well tolerated by medical treatment. It shows that 125I seed implantation combined with Apatinib is effective and safe in the treatment of locally advanced lung cancer.

**Keywords:** Apatinib mesylate tablets; 125I seed; locally advanced stage; lung tumour

**DOI:** <https://doi.org/10.47391/JPMA.1442>

### Introduction

In recent years, the incidence and mortality of lung cancer has increased rapidly, ranking first among all malignant tumours.<sup>1</sup> Local control is the main treatment for advanced lung cancer,<sup>2</sup> combined with radiotherapy, chemotherapy, target therapy and immunotherapy to improve local control rate, alleviate clinical symptoms, improve quality of life and prolong survival.<sup>3</sup> Radioactive 125I seed implantation therapy began in the 1970s and has played an active role in the clinical treatment of various tumours. Radioactive 125I seeds continuously emit low dose gamma rays with a half-life of 60.1 days and an effective radiation radius of 1.7 cm. It can effectively kill tumour cells without causing radiation damage to normal surrounding tissues. Radioactive seed implantation therapy can act on every

<sup>1</sup>Department of Oncology, Characteristic Medical Center of Chinese People's Armed Police Force, Tianjin, China; <sup>2,3</sup>Department of Thoracic Surgery, Tianjin First Central Hospital, Tianjin, China.

**Correspondence:** Xiaoping Li. e-mail: [eonelp@163.com](mailto:eonelp@163.com)

cycle of cancer cells, leading to apoptosis and also inducing activation of tumour suppressor genes in the quiescent phase, destroy DNA and kill cancer cells. However, due to the limitations of this local treatment, combination of systemic therapy was recommended to achieve satisfactory results in clinical practice.<sup>4</sup> Apatinib, as a new tyrosine inhibitor targeting VEGFR2, has been widely used in lung cancer patients who failed in second or third line chemotherapy,<sup>5</sup> especially in advanced lung cancer patients with negative driving gene. Studies have shown that antiangiogenic therapy can improve radioresistance.<sup>6</sup> We retrospectively analysed 19 locally advanced lung cancer patients, treated with 125I implantation, and evaluated the short-term efficacy and safety of combination therapy with Apatinib.

### Case Report

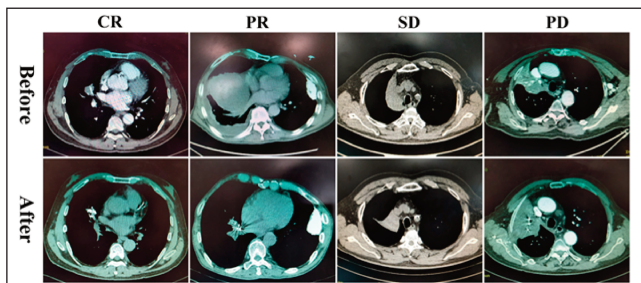
Nineteen locally advanced lung cancer patients, diagnosed by clinical and pathological examination, who had lost the chance of one-stage surgery and had no distant metastasis at that time, were analysed. Target therapy was excluded due to the negative driving gene after NGS, and also because they refused chemotherapy, radiotherapy and immunotherapy. According to the treatment intention, 12 patients (treatment group) received oral Apatinib maintenance therapy after 125I implantation. The drug regimen was Apatinib Mesylate tablets (Jiangsu Hengrui Pharmaceutical Co., Ltd. Atan, 250 mg/tablet, national medicine standard word H20140103), taken orally 30 minutes after breakfast, 1 tablet/day, the patients were asked to stop taking medicine if intolerable adverse reactions occurred. Seven patients (control group) underwent only symptomatic supportive treatment after 125I implantation. All the patients were fully informed of their condition and signed informed consent. The authors followed up the short-term survival, imaging and related factors of the patients for six months.

Lung CT was performed before 125I implantation and every two months after the implantation. The overall response rate (ORR) and disease control rate (DCR) at six months after implantation was also assessed. Serum IL-2R, IL-6 and TNF- $\alpha$  were measured by chemical fluorescent enzyme immunoassay before and one month after 125I implantation. Complications of 125I implantation mainly

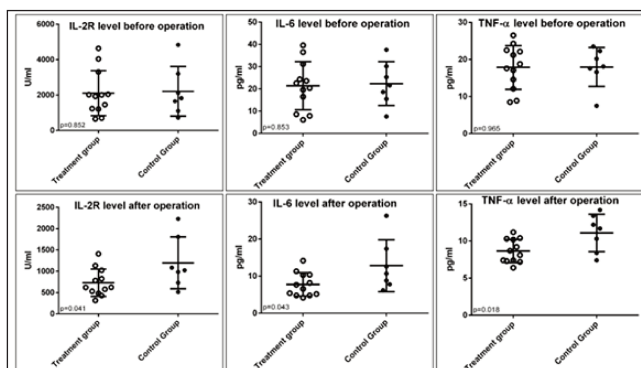
**Table:** Baseline data of patients in the two groups.

		Treatment group (n=12)	Control group (n=7)	p-value
Sex	male	9 (75%)	6 (85.7%)	0.475
	female	3 (25%)	1 (14.3%)	
Age(years)	≤65	5 (41.7%)	3 (42.9%)	0.663
	>65	7 (58.3%)	4 (57.1%)	
Smoking history	yes	8 (66.7%)	5 (71.4%)	0.378
	no	4 (33.3%)	2 (28.6%)	
Histology	NSCLC	SC	7 (58.3%)	0.117
		AC	3 (25%)	
	SCLC	2 (16.7%)	2 (28.6%)	
Clinical stages	≤III A	3 (25%)	2 (28.6%)	0.634
	III B	9 (75%)	5 (71.4%)	
PS	0-1	7 (58.3%)	4 (57.1%)	0.663
	≥2	5 (41.7%)	3 (42.9%)	

NSCLC: Non-small cell lung cancer. SCLC: Small cell lung cancer. SC: Squamous Carcinoma. AC: Adenocarcinoma. PS: Performance status.



**Figure-1:** Evaluation of short-term efficacy of patients by RECIST solid tumour criteria.



**Figure-2:** Serum levels of IL-2R, IL-6 and TNF-α before and after 125I implantation in the two groups.

included bleeding due to puncture, haemothorax, pneumothorax, haemoptysis, and pleural effusion within one week of the operation. The main side effects of Apatinib were hypertension, proteinuria, hand-foot skin reaction, diarrhoea, rash and haemorrhage within six months.

There was no significant difference in the baseline data of patients between the two groups ( $p > 0.05$ , Table). After six months, according to RECIST solid tumours evaluation criteria 1.1, there were CR in 1 case (8.3%), PR in 9 cases

(75%), SD in 1 case, PD in 1 case (8.3%), the ORR was 83.3% (10/12) and the DCR was 91.7% (11/12), while in the control group, there were no CR cases, PR in 3 cases (42.9%), SD in 2 cases, PD in 2 cases (28.6%), the ORR was 42.9% (3/7) and DCR was 71.4% (5/7). (Figure 1 shows typical cases). One control patient developed new bone metastases.

Before 125I implantation IL-2R, IL-6 and TNF-α were higher than normal reference values in all the patients, and there was no statistical difference between the two groups. One month after 125I implantation, the difference appeared. The decrease in treatment group was more obvious, and there were statistical differences between the two groups ( $p < 0.05$ , Figure 2).

There was no significant difference in the side-effects of implantation between the two groups, ( $p > 0.05$ ). The common side effects and classification are mainly based on the instructions of Apatinib Mesylate tablets and Common Terminology Criteria for Adverse Events according to National Cancer Institute.<sup>7</sup> In the treatment group, I-II degree hypertension (7/12), I-II degree proteinuria (3/12), I-II degree mouth cavity mucositis (4/12) and diarrhoea of degree I to II (3/12) could be controlled by medication. No patient stopped medication or changed treatment plan.

### Discussion

In recent years, a large number of studies have shown that<sup>8</sup> 125I is effective in the treatment of lung cancer with high local control rate and less toxic side effects. Although the local control rate is high, which is consistent with our combined therapy patients, still some patients progressed, and one patient even developed new metastatic lesion. Relevant guidelines<sup>9</sup> recommend that systemic therapy should be the main treatment for lung cancer, but for patients who refuse chemoradiotherapy and with negative driving genes, finding a synergistic and safe oral medicine is particularly important.

Apatinib is a small molecule tyrosine kinase inhibitor of VEGFR independently developed in China. Pharmacodynamic studies have shown that Apatinib can block the signal transduction after binding to VEGFR, and lead to the inhibition of angiogenesis.<sup>10</sup> Increased hypoxia in tumour can cause radiotherapy resistance, many evidences show that combination of anti-angiogenesis drugs and radiotherapy can increase the therapeutic effect.<sup>11</sup> In our study, patients in the treatment group showed better effects, possibly because Apatinib normalised the blood vessels in the tumour, and thereby improved the blood perfusion ability and ultimately enhanced radiosensitivity. Apatinib can also down-regulate the level of vascular growth factors to increase the apoptosis of cancer cells. Studies have shown that 125I

implantation can directly kill adjacent cancer cells, but also stimulate angiogenesis.<sup>12</sup> So the combination of antiangiogenic therapy can improve the efficacy of each other in theory, which was confirmed by our cases.

The study showed that the short-term effect of treatment group was obvious, this result was also verified in the monitoring of serum related factors. IL-2R, IL-6 and TNF- $\alpha$  of lung cancer patients were usually higher before therapy; the treatment group patients showed obvious improvement after relevant treatment, which indicated that the combination played an active role in improving the immune status. Although Apatinib increased some related side effects, all the patients were able to complete the six-month treatment cycle without interruption or withdrawal. Therefore, it can be said that the combined therapy not only achieved a good therapeutic effect, but also showed good safety.

### Conclusion

The study showed that 125I implantation combined with Apatinib is effective and safe in the treatment of locally advanced lung cancer with negative driving gene, which provides a new treatment method for the future.

**Disclaimer:** None.

**Conflict of Interest:** None.

**Funding Sources:** None.

### References

1. Chen W, Zheng R, Baade PD, Zhang S, Zeng H, Bray F, et al. Cancer statistics in China, 2015. *CA Cancer J Clin* 2016;66:115-32. doi: 10.3322/caac.21338.
2. Han D, Heuvelmans MA, Vliegthart R, Rook M, Dorrius MD, Oudkerk M. An Update on the European Lung Cancer Screening Trials and Comparison of Lung Cancer Screening Recommendations in Europe. *J Thorac Imaging* 2019;34:65-71. doi: 10.1097/RTI.0000000000000367.
3. Li X, Yang B, Ren H, Xiao T, Zhang L, Li L, et al. Hsa\_circ\_0002483 inhibited the progression and enhanced the Taxol sensitivity of non-small cell lung cancer by targeting miR-182-5p. *Cell Death Dis* 2019;10:953. doi: 10.1038/s41419-019-2180-2.
4. Zhang S, Zheng Y, Yu P, Yu F, Zhang Q, Lv Y, et al. The combined treatment of CT-guided percutaneous 125I seed implantation and chemotherapy for non-small-cell lung cancer. *J Cancer Res Clin Oncol* 2011;137:1813-22. doi: 10.1007/s00432-011-1048-3.
5. Song Z, Yu X, Lou G, Shi X, Zhang Y. Salvage treatment with apatinib for advanced non-small-cell lung cancer. *Onco Targets Ther* 2017;10:1821-5. doi: 10.2147/OTT.S113435.
6. Choi YJ, Heo K, Park HS, Yang KM, Jeong MH. The resveratrol analog HS-1793 enhances radiosensitivity of mouse-derived breast cancer cells under hypoxic conditions. *Int J Oncol* 2016;49:1479-88. doi: 10.3892/ijo.2016.3647.
7. U.S. Department of Health and Human Services. Common Terminology Criteria for Adverse Events (CTCAE) Version 5.0. [Online] 2017 [Cited 20201 February 14]. Available from URL: [https://ctep.cancer.gov/protocoldevelopment/electronic\\_applications/docs/ctcae\\_v5\\_quick\\_reference\\_5x7.pdf](https://ctep.cancer.gov/protocoldevelopment/electronic_applications/docs/ctcae_v5_quick_reference_5x7.pdf)
8. Colonias A, Betler J, Trombetta M, Bigdeli G, Gayou O, Keenan R, et al. Mature follow-up for high-risk stage I non-small-cell lung carcinoma treated with sublobar resection and intraoperative iodine-125 brachytherapy. *Int J Radiat Oncol Biol Phys* 2011;79:105-9. doi: 10.1016/j.ijrobp.2009.10.030.
9. Wood DE. National Comprehensive Cancer Network (NCCN) Clinical Practice Guidelines for Lung Cancer Screening. *Thorac Surg Clin* 2015;25:185-97. doi: 10.1016/j.thorsurg.2014.12.003.
10. Zhang H. Apatinib for molecular targeted therapy in tumor. *Drug Des Devel Ther* 2015;9:6075-81. doi: 10.2147/DDDT.S97235.
11. Xiang GL, Zhu XH, Lin CZ, Wang LJ, Sun Y, Cao YW, et al. 125I seed irradiation induces apoptosis and inhibits angiogenesis by decreasing HIF-1 $\alpha$  and VEGF expression in lung carcinoma xenografts. *Oncol Rep* 2017;37:3075-83. doi: 10.3892/or.2017.5521.
12. Meijer TW, Kaanders JH, Span PN, Bussink J. Targeting hypoxia, HIF-1, and tumor glucose metabolism to improve radiotherapy efficacy. *Clin Cancer Res* 2012;18:5585-94. doi: 10.1158/1078-0432.CCR-12-0858.