

Intravenous drug abusers presenting with pseudoaneurysm and other surgical complications in Pakistan

Muhammad Amar Qudeer¹, Syed Asghar Naqi², Muhammad Zeeshan Sarwar³, Hafiza Amina Mujahid⁴

Abstract

People who inject drugs (PWIDs) reuse injection equipment and other paraphernalia, which is a major source of transmission of human immunodeficiency (HIV) and hepatitis C virus (HCV) infections. PWIDs who use infected injections develop many surgical complications which are life-threatening. The most common complication is infected pseudoaneurysm. To assess complications requiring surgery in drug abusers, a study was conducted in the East Surgical Ward of Mayo Hospital Lahore, Pakistan from Jan 2017 to Jan 2019.

A total of 48 PWIDs presented to the surgical department, out of which 39 (81%) were HIV positive, and 31 (64%) were HCV positive. Of the 52% who had pseudoaneurysm, 92% had femoral and popliteal aneurysm and 8% had brachial aneurysm. After ligation and excision of pseudoaneurysm only 8% required major amputation. Mortality rate was 0%. Ligation and excision is a safe option in pseudoaneurysm. Most common site for pseudoaneurysm was left femoral artery.

Keywords: Drug users, False aneurysm, HIV and HCV, Ligation, Amputation.

DOI: <https://doi.org/10.47391/JPMA.644>

Introduction

Pakistan is one of the countries in the world that are most affected with drugs addiction. Data from United Nations Office on Drugs and Crime (UNODC) show that there are 7.6 million drug addicts in Pakistan. and the number is increasing at the rate of 40,000 per year.^{1,2} PWIDs are at risk of acquiring blood-borne infections, including HIV, HCV, HBV.³ In July 2015, the Senate Committee of Interior and Narcotics Control informed that 700 people die each day due to drug addiction-related complications. Also, Pakistan is among the top four countries in Asia where the number of cases of new HIV infections is increasing year by year, especially among PWIDs.⁴

The common sites for injecting drugs among PWIDs are

¹King Edward Medical University and Mayo Hospital, Lahore, Pakistan;

^{2,3}Department of Surgery, King Edward Medical University and Mayo Hospital, Lahore, Pakistan; ⁴King Edward Medical University, Lahore, Pakistan.

Correspondence: Muhammad Amar Qudeer. e-mail: mq410804@gmail.com

femoral triangle, popliteal fossa and cubital fossa. Repeated injections in these areas lead to vascular injury which results in the formation of pseudoaneurysm on these sites. All these aneurysms are infected, which is a major problem in dealing with these vascular pseudoaneurysms. Controversy exists whether pseudoaneurysm be dealt with ligation and excision or revascularisation. Keeping these controversies of optimal surgical management in mind, this paper provides useful information which can contribute to the epidemiology of pseudoaneurysms and surgical techniques used for their treatment and their clinical outcome in a population of drug abusers presenting to Mayo Hospital, Lahore.

Case Series

This Case Series was carried out in the East Surgical Ward of Mayo Hospital, Lahore. The duration of the study was two years, from January 2017 to January 2019. Drug addicts of either gender, presenting in surgical emergency and out-patient department (OPD) were included in this study. Diagnosis was made on clinical examination that showed hot, large, tense swelling which was bleeding or was about to bleed, visible pulsation or presence of clots at the site of injections in patients with a history of drug use by intravenous injections.

A total of 48 drug addict patients presented in surgical emergency and out-patient department. Out of these 48, 45 (93.7%) presented through emergency and 3 (6.2%) presented through-out patient department. Their age ranged from 18 to 55 years with mean age of 31 years. All patients were male. On initial screening, 39 (81.2%) patients were HIV positive, 31 (64.5%) patients were HCV positive and 1(2%) patients were HBV positive (Table-1).

Most common presentation was pseudoaneurysm (5 [52.0%]). A total of 2 (8%) had brachial pseudoaneurysm, 01 (4%) had left popliteal pseudoaneurysm and 22 (88%)

Table-1: Status on initial screening (n=48).

Infections	Positive cases n (%)
HIV	39 (81)
HCV	31(64)
HBV	1 (2)

HIV Human immunodeficiency virus, HCV Hepatitis C virus , HBV Hepatitis B virus.

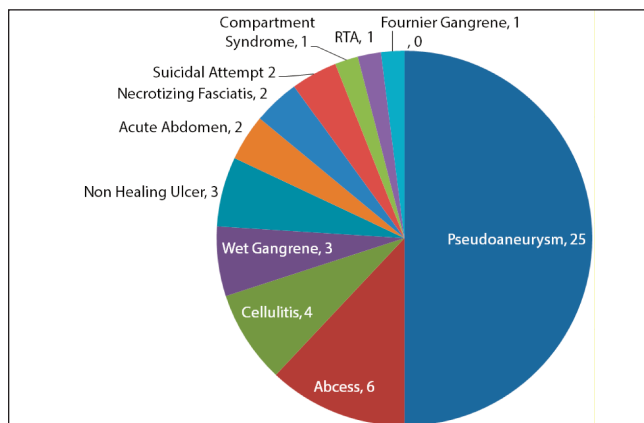


Figure: Presentation of Drug Addicts.

Table-2: Rate of amputation after pseudoaneurysm excision.

Diagnosis	No of cases	Treatment option	Major amputation
Pseudoaneurysm	24	Vessel ligation and excision of pseudoaneurysm	2(8%)
Pseudoaneurysm with ischaemic limb	01	Major amputation	1(100%)

had femoral pseudoaneurysm (Table-2), out of which 14 (63.6%) had left femoral pseudoaneurysm while 8 (36.3%) had right femoral pseudoaneurysm. All brachial aneurysms were on the left side. Most common presentation was bleeding from pseudoaneurysm (20 out of 25 (80%)). A total of 3 (6%) cases presented with wet gangrene.

Among the cases of femoral pseudoaneurysm, common iliac artery was ligated in one case only. Ligation was done through lower midline approach due to large infected pseudoaneurysm involving common femoral and external iliac artery. External iliac was ligated in two cases. Common femoral was ligated in 20 cases. On follow-up, one disarticulation and one above-knee amputation had to be performed due to ischaemic changes after ligation of femoral vessel. The popliteal pseudoaneurysm patient underwent above-knee amputation due to ischaemic changes at the time of presentation. Among the brachial artery pseudoaneurysm patients, brachial artery was ligated and debridement of necrotic tissue was done. The rate of major amputation after ligation of vessel and excision of pseudoaneurysm was 08% (Table-3).

Other than pseudoaneurysm, presentation of drug addicts in surgical emergency and/or OPD was quite different. A total of 4 (8%) cases presented with cellulitis, which were managed conservatively/ non-operative protocol. Six (12%) patients presented with abscess formation for which incision and drainage was carried out. Only three patients presented with non-healing ulcer. Also, 2 (4%) cases presented with acute abdomen for which exploratory

laparotomy was done. One was enteric perforation for which double barrel ileostomy was performed while the second patient had adhesion obstruction for which adhesion lysis was done. One patient presented with compartment syndrome for which fasciotomy was performed. Among the 48 patients, only 2 (4%) presented with necrotizing fasciitis and one presented with Fournier gangrene; debridement was carried out in all three cases. Two (4%) patients presented with suicidal cut throat for which neck exploration was performed. No vascular injury was found and primary repair of neck muscles was done.

Mortality rate was zero. A total of 41(85.4%) patients were discharged. While 4 (8.3%) cases left against medical advice and 3 (6.2%) absconded after treatment.

Discussion

According to the data available at National AIDS Control Programme (NACP) there are an estimated 0.165 million HIV positive people in Pakistan. The surveillance report of 2016 indicates that PWIDs have the highest prevalence of HIV infection (38.4%). About 31% reported sharing syringes and needles, exposing themselves to the risk of infection.

In our study 25 (52.0%) drug abusers developed pseudoaneurysm and the most common site for it was left femoral artery. About 14 (63.6%) femoral pseudoaneurysms were on the left side and all brachial aneurysm were of left brachial artery. Since most of our population is right-handed, it is easy to inject in the left femoral artery. In contrast to this, a study conducted by Arora et al⁷ from George Washington University School of Medicine showed that all patients had right-sided femoral pseudoaneurysm. Geographical difference may be the reason for this variation.

Among intravenous drug abusers, vascular trauma is a major problem. Repeated needle injury to the vessel leads to damage to the vascular wall which causes the formation of pseudoaneurysm. There are multiple options to treat pseudoaneurysm which include ligation of major vessel and debridement only, or immediate or delayed revascularisation after excision of pseudoaneurysm. Percutaneous thrombin injection, or coil embolisation can also be used.

In this study, we adopted the option to ligate femoral/iliac vessel to take control, and then debridement of infected, necrotic tissue. Study results show that this is a safe option in an emergency setting in case of infected bleeding and infected pseudoaneurysm in drug addicts with post ligation major amputation rate of 8%.

A study was conducted by Levi N, et al at the Department of Vascular Surgery, Rigshospitalet, University Hospital of

Copenhagen, Denmark, showed amputation rate of 11% to 33% after ligation of femoral vessel in pseudoaneurysm and recommended revascularisation for better outcome.⁵ Another study conducted by Frank Padberg et al showed 17% amputation rate after revascularisation and recommended ligation and excision as a safe option for pseudoaneurysm.⁶ Revascularisation was frequently accompanied by life-threatening secondary complications. A study by Arora S, et al showed that common femoral artery ligation and debridement is a safe mode of treatment in infected pseudoaneurysm.⁷ A study conducted by S. A Naqi et al showed 17% major amputation rate after ligation and excision of pseudoaneurysm and concluded that ligation and debridement in infected pseudoaneurysm is a safe and effective treatment.⁸ Another study conducted by Colin Peirce stated that after ligation and debridement for pseudoaneurysm in 11 patients only 01 patient needed major amputation, which shows that ligation and debridement was well-tolerated in these patients.⁹

In his study, Lewis Jr reported that drug abusers sometimes use subclavian and internal jugular veins for injections which lead to life-threatening complications.¹⁰ Revascularisation after ligation and excision can be achieved by graft which can be either synthetic or autogenous. But the infected area remains the major limitation in revascularisation. Availability of synthetic graft in developing countries always remains as a major limitation.

Infection prevention control (IPC) measures were taken to prevent HIV transmission during the procedures. Operation theatre movement was restricted and only concerned people were allowed to enter. Preventive measures also included the use of disposable theatre gowns and mask, etc. After the case was handled, waste was disposed of according to infection prevention control protocol.

Conclusion

Ligation of femoral vessel and debridement of infected necrotic tissue is a safe option for pseudoaneurysm in emergency. Disarticulation rate after ligation of femoral vessel is low and acceptable in an emergency setting.

Disclaimer: None.

Conflict of interest: None.

Funding disclosure: None.

References

1. United Nations Office on Drugs, Crime. World drug report 2010. United Nations Publications; 2010.
2. The Nation. [Online] [Cited 2019 July 12]. Available from: URL: <https://nation.com.pk/10-Feb-2018/drug-abuse-in-pakistan-reaches-alarming-level>.
3. Bergenstrom A, Achakzai B, Furqan S, ul Haq M, Khan R, Saba M. Drug-related HIV epidemic in Pakistan: a review of current situation and response and the way forward beyond 2015. *Harm Reduct J* 2015; 12: 43.
4. Achakzai AB, Furqan S, ul Haq M, Khan R, Saba M. Drug-related HIV epidemic in Pakistan: a review of current situation and response and the way forward beyond 2015. *Harm Reduct J* 2015; 12: 43.
5. Levi N, Rørdam P, Jensen LP, Schroeder TV. Femoral pseudoaneurysms in drug addicts. *Eur J Vasc Endovasc Surg* 1997; 13: 361-2.
6. Padberg Jr F, Hobson II R, Lee B, Anderson R, Manno J, Breitbart G, et al. Femoral pseudoaneurysm from drugs of abuse: ligation or reconstruction? *J Vasc Surg* 1992; 15: 642-8.
7. Arora S, Weber MA, Fox CJ, Neville R, Lidor A, Sidawy AN. Common femoral artery ligation and local debridement: a safe treatment for infected femoral artery pseudoaneurysms. *J Vasc Surg* 2001; 33: 990-3.
8. Naqi S, Khan H, Akhtar S, Shah T. Femoral pseudoaneurysm in drug addicts—excision without revascularisation is a viable option. *Eur J Vasc Endovasc Surg* 2006; 31: 585-7.
9. Peirce C, Coffey J, O'Grady H, Aly S, O'Malley K, O'Donohoe M. The management of mycotic femoral pseudoaneurysms in intravenous drug abusers. *Ann Vasc Surg* 2009; 23: 345-9.
10. Lewis Jr JW, Groux N, Ellicott Jr JP, Jara FM, Obeid FN, Magilligan Jr DJ. Complications of attempted central venous injections performed by drug abusers. *Chest* 1980; 78: 613-7.