

VATS thoracoscopic decortication for empyema thoracic: A retrospective experience and analysis of 162 cases

Farhan Ahmad Majeed¹, Sohail Saqib Chatha², Usama Zafar³, Ahmad Ali⁴, Nabeela Farhan⁵, Ahmad Raza⁶

Abstract

Objective: To analyse the experience of empyema thoracis management using video-assisted thoracoscopic surgery.

Method: The retrospective study was conducted at the Combined Military Hospitals, Rawalpindi and Lahore, Pakistan, and comprised data of empyema thoracis cases who underwent thoracoscopic decortications by the same consultant surgeon between January 2009 and 2018. Uniportal or multiportal video-assisted thoracoscopic decortications was performed. Histopathology and microbiological sampling were done in all cases.

Results: Of the 162 cases, 114(70.4%) were males and 48(29.6%) were females. The overall mean age was 44±16.37 years. Three ports were utilised in 58(36%) patients. Hospital stay of 122(75.3%) patients was <5 days post-procedure. Post-thoracotomy neuralgia occurred in 19(11.7%) patients, while 9(5.5%) had surgical site infection. Overall complications were 30(18.5%). There was no mortality.

Conclusion: Video-assisted thoracoscopic decortications was found to be a safe, effective and efficient procedure.

Keywords: VATS, Decortication, Empyema thoracis. (JPMA 71: 502; 2021) DOI: <https://doi.org/10.47391/JPMA.431>

Introduction

Empyema thoracis is defined as pus in the pleural cavity, and the most common cause of it is post- or parapneumonic.¹⁻³ Other causes include tuberculosis (TB), post-trauma,⁴ post-surgery or as a complication of abdominal infections. Empyema is divided into three phases: exudative phase stage 1 which occurs due to increased permeability of the pleura; fibrinopurulent phase stage 2 which occurs due to fibrin deposition resulting in loculation of fluid, formation of pleural peel and development of frank pus; and organising phase stage 3 which results in thickening of the layers and restricting the movement of lung, chest and diaphragm. Treatment of empyema depends upon the stage of the empyema at the time of diagnosis and presentation. Stage 1 can be treated with appropriate antibiotic treatment and tube thoracostomy, and rarely needs surgical intervention,⁵ but the intervention and diagnosis should be prompt. In the other two stages, surgical treatment in the form of tube thoracostomy or surgical decortications is employed. Traditionally, open thoracotomy has been considered the gold standard for decortication in empyema thoracis patients, but it causes increased morbidity and post-operative pain.⁶ In recent literature, video-assisted thoracoscopic decortications (VATS) has been cited as a safe and effective alternative procedure with less pain and

morbidity.⁷ There have been a number of studies favouring VATS in the treatment of empyema thoracis.⁸⁻¹⁰ Studies have established the efficacy of VATS in drainage of the early phase empyema^{11,12} but its role in decortications of the lung in later phase is still under debate.^{13,14} The current study was planned to analyse the outcome and complication of VATS in patients of early and chronic empyema.

Patients and Methods

The retrospective study was conducted at the Combined Military Hospital (CMH) Rawalpindi, and CMH Lahore, Pakistan, and comprised data of empyema thoracis cases who underwent thoracoscopic decortications by the same consultant surgeon between January 2009 and 2018.

The sample size was calculated using online Raosoft calculator¹⁵ with confidence level 95%, margin of error 5% and approximate population size 300 presenting to the Thoracic Surgery Department with complaints of empyema.

Those included were patients with established empyema, and stage of empyema was determined by clinical examination, chest X-ray and computed tomography (CT) scan of the chest. Patients with early and late stage of empyema were included. Patients of clotted haemothorax, malignant pathology of chest and conversion to open thoracotomy were excluded. Decision to proceed with VATS decortication was taken by the consultant based upon clinical indications and empyema staging. All cases were given local block at the sites of ports after procedure and post-operative with non-steroidal anti-inflammatory drugs

^{1,3}Combined Military Hospital, Multan, Pakistan; ²Pakistan Air Force Hospital, Lahore, Pakistan; ⁴Combined Military Hospital, Lahore, Pakistan; ⁵Cantonment Hospital, Lahore, Pakistan; ⁶Combined Military Hospital, Kharian, Pakistan.

Correspondence: Sohail Saqib Chatha e-mail: drsohailchatha@hotmail.com

(NSAIDs). Aetiology and stage of empyema, ports used for VATS, hospital stay, post-thoracotomy neuralgia (PTN) and complications were recorded for all patients.

Results

Of the 162 cases, 114(70.4%) were males and 48(29.6%) were females. The overall mean age was 44±16.37 years (12-70 years). Of the total, 120(74) cases were of early stage of empyema (Table).

Table: Baseline demographics.

Variable		n (%)
Gender	Male	114 (70.4)
	Female	48 (29.6)
Year	2009	10 (6.1)
	2010	8 (4.9)
	2011	14 (8.6)
	2012	20 (12.3)
	2013	19 (11.7)
	2014	21 (12.9)
	2015	26 (16.1)
	2016	16 (9.8)
Grade of empyema	Early	120 (74)
	Late	42 (26)
Hospital Stay	Less than 5 days	122 (75.3)
	More than 5 days	40 (24.7)

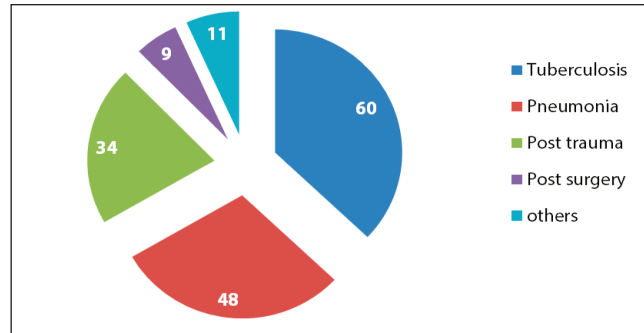


Figure-1: Aetiology of the empyema.

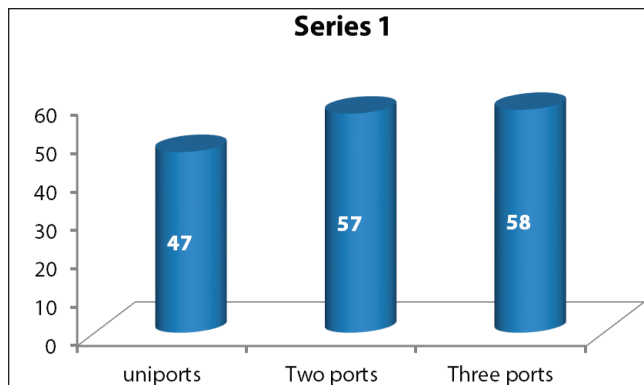
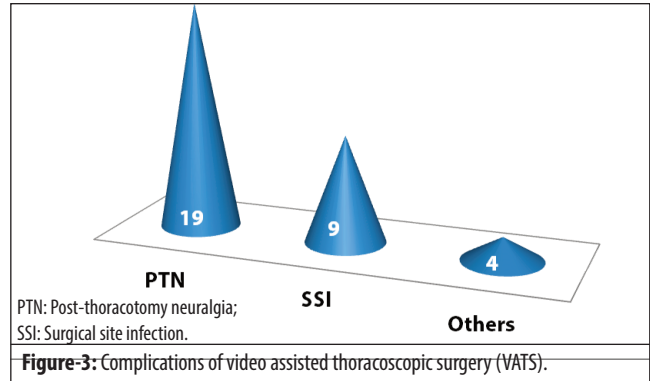


Figure-2: Types of video assisted thoracoscopic surgery (VATS).



PTN: Post-thoracotomy neuralgia;
SSI: Surgical site infection.

Figure-3: Complications of video assisted thoracoscopic surgery (VATS).

The most common aetiology of empyema was TB 60 (37%), followed by pneumonia 48(29.6%), post-trauma 34(20.9%)and post-surgical 9(5.5%) (Figure 1).

Uniportal VATS was utilised in 47(29%) patients, two ports were used in 57(35%) and three ports were utilised in 58(36%) patients (Figure 2).

Single chest tube was placed after VATS in 138(85.18%) patients which was removed after mean period of 3±1.96 post-op days, while in 24(14.81%) cases two chest tubes were placed, where the first tube was removed after 1.0±1.9 days and the second tube was removed after 7.0±4.3 days. Overall, 8(4.9%) cases had unsatisfactory post-op X-ray while clinical and radiological expansion of the lung was seen in 154(95%) cases. Hospital stay was divided into two groups, those staying >5 days and those with <5 days. Of all the patients, 122(75.3%) had stayed <5 days and 40(24.7%) stayed >5 days post-procedure. Complications occurred in 30(18.5%) patients among which PTN was most common 19(11.7%) (Figure 3). There was no mortality amongst the patients.

Discussion

Successful management of empyema thoracis requires early recognition of the disease and aggressive treatment depending upon the stage of the disease. Surgical treatment is considered in cases of loculated effusions, especially if lungs fail to expand after the drainage. The main aim of surgical treatment for empyema thoracis is to drain all the loculated effusions and ensuring lung expansion by removing the pleural peel from the lung surface. Thoracoscopy has been found to be an effective treatment modality for empyema, especially if lungs fail to re-expand after drainage.¹⁶ Initially VATS was used mostly for confirmation of empyema thoracis, but with advances in technology and surgical expertise, VATS debridement has been found to be very effective method of treating early stages of empyema and now its effectiveness in treatment of multi-loculated and chronic empyema has also been reported in literature.¹⁷ In our series there were

42 cases of chronic empyema which were successfully treated by using VATS. VATS is considered more effective than tube drainage because minimal success is reported with tube thoracostomy and 36-65% patients are not cured¹⁸ with prolonged hospital stay and morbidity.¹⁹ In the current study, there were only 8(4.9%) cases of unsatisfactory post-op X-ray and only 4(2.4%) recurrences after 1 month of follow-up. The success rate in the current study was 95% compared to a reported success rate of 80%.²⁰ Post-operative hospital stay in our series was <5 days in 75% cases, while a study reported average number of postoperative hospital stays in case of patients who underwent thoracoscopy to be 7.8 days, and in another study it was 12.3 days.^{21,22} In one study, average hospital stay was 5 days which is almost similar to the current findings. In our study, major aetiology of empyema was TB 60(37%), and similar incidence of aetiology has been reported earlier.²³

The current study has few limitations as it was a retrospective study and there were no comparison groups. Moreover, majority of the patients had early empyema so efficacy of VATS in late stages of empyema still needs to be determined with a different study population.

Conclusion

VATS was found to be a safe, effective and efficient procedure which reduced overall hospital stay and caused minimal complications in the management of empyema thoracis.

Disclaimer: None.

Conflict of interest: None.

Source of funding: None.

References

- Mandal AK, Thadepalli H, Mandal AK, Chettipally U. Outcome of primary empyema thoracis: Therapeutic and microbiologic aspects. *Ann Thorac Surg* 1998; 66: 1782-6.
- DeSouza A, Offner PJ, Moore EE, Biffl WL, Haenel JB, Franciose RJ, et al. Optimal management of complicated empyema. *Am J Surg* 2000; 180: 507-11.
- Lackner RP, Hughes R, Anderson LA, Sammut PH, Thompson AB. Video-assisted evacuation of empyema is the preferred procedure for management of pleural space infections. *Am J Surg* 2000; 179: 27-3.
- Meyer DM, Jessen ME, Wait MA, Estrera AS. Early evacuation of traumatic retained hemothoraces using thoracoscopy: A prospective, randomized trial. *Ann Thorac Surg* 1997; 64: 1396-401.
- Tong BC, Hanna J, Toloza EM, Onaitis MW, D'Amico TA, Harpole DH, et al. Outcomes of video-assisted thoracoscopic decortication. *Ann Thorac Surg* 2010; 89: 220-5.
- Shin JA, Chang YS, Kim TH, Haam SJ, Kim HJ, Ahn CM, et al. Surgical decortications as the first-line treatment for pleural empyema. *J Thorac Cardiovasc Surg* 2013; 145: 933-9.
- Rogers ML, Duffy JP. Surgical aspects of chronic post-thoracotomy pain. *Eur J Cardiothorac Surg* 2000; 18: 711-6.
- Rzyman W, Skokowski J, Romanowicz G, Lass P, Dziadziuszko R. Decortication in chronic pleural empyema - effect on lung function. *Eur J Cardiothorac Surg* 2002; 21: 502-7.
- Luh SP, Chou MC, Wang LS, Chen JY, Tsai TP. Video-assisted thoracoscopic surgery in the treatment of complicated parapneumonic effusions or empyemas: outcome of 234 patients. *Chest* 2005; 127: 1427-32.
- Cardillo G, Carleo F, Carbone L, Di Martino M, Salvadori L, Petrella L, et al. Chronic postpneumonic pleural empyema: comparative merits of thoracoscopic versus open decortication. *Eur J Cardiothorac Surg* 2009; 36: 914-8.
- Chen B, Zhang J, Ye Z, Ye M, Ma D, Wang C, et al. Outcomes of video-assisted thoracic surgical decortications in 274 patients with tuberculous empyema. *Ann Thorac Cardiovasc Surg* 2015; 21: 223-8.
- Lee H, Park S, Shin H, Kim K. Assessment of the usefulness of video-assisted thoracoscopic surgery in patients with non-tuberculous thoracic empyema. *J Thorac Dis* 2015; 7: 394-9.
- Waller DA, Rengarajan A. Thoracoscopic decortication: a role for video-assisted surgery in chronic postpneumonic pleural empyema. *Ann Thorac Surg* 2001; 71: 1813-6.
- Cheng YJ, Wu HH, Chou SH, Kao EL. Video-assisted thoracoscopic surgery in the treatment of chronic empyema thoracis. *Surg Today* 2002; 32: 19-25.
- Anon. [Online] 2019 [Cited 2018 March 2]. Available from: URL: <https://www.calculator.net/sample-size-calculator.html>.
- Cassina PC, Hauser M, Hillejan L, Greschuchna D, Stamatis G. Video-assisted thoracoscopy in the treatment of pleural empyema: Stage-based management and outcome. *J Thorac Cardiovascular Surg* 1999; 117: 234-8.
- Drain AJ, Ferguson JI, Sayeed R, Wilkinson S, Ritchie A. Definitive management of advanced empyema by two-window video-assisted surgery. *Asian Cardiovasc Thorac Ann* 2007; 15: 238-9.
- Landreneau RJ, Keenan RJ, Hazelrigg SR, Mack MJ, Naunheim KS. Thoracoscopy for empyema and hemothorax. *Chest* 1995; 109: 18-24.
- Ridley PD, Braimbridge MV. Thoracoscopic debridement and pleural irrigation in the management of empyema thoracis. *Ann Thorac Surg* 1991; 51: 461-64.
- Kalawsa R, Agrawal A, Palekar HD. Prospective study of thoracoscopy in empyema patients. *Int Surg J* 2018; 5: 2767-70.
- Hornick P, Clark D, Townsend E, Fountain W. Video thoracoscopy in the treatment of early empyema: an initial experience. *Ann R Coll Surg Engl* 1996; 78: 45-8.
- Striffeler H, Gugger M, ImHof V, Cerny A, Furrer M, Ris HB. Video-assisted thoracoscopic surgery for fibrinopurulent pleural empyema in 67 patients. *Ann Thorac Surg* 1998; 65: 319-23.
- Acharya PR, Shah KV. Empyema thoracis: a clinical study. *Ann Thorac Med* 2007; 2: 14-7.