

Effects of different polyvinylpyrrolidone iodine concentrations on trismus and swelling following third molar surgery

Esra Yuce¹, Omur Dereci², Nazli Altin³, Cansugul Efeoglu Koca⁴, Murude Yazan⁵

Abstract

Objective: To compare the clinical efficacy of different povidone iodine concentrations for the management of postoperative pain and swelling following mandibular third molar surgery.

Methods: The randomised, prospective, double-blind and controlled study was conducted from October 2016 to January 2018 at the Department of Oral and Maxillofacial Surgery, Faculty of Dentistry, Biruni University, Istanbul, Turkey, and comprised individuals aged 18-30 years who underwent surgical removal of pathology-free completely unerupted mandibular lower third molars. The participants were randomly assigned to four groups: Group I had saline-only controls, Group II was given 0.5% concentration of povidone iodine, Group III had 1% concentration of povidone iodine, and Group IV had 3% concentration of povidone iodine. Facial swelling and trismus were assessed on the 2nd and 7th postoperative days. Data was analysed using SPSS 22.

Results: Of the 80 patients, 34(42.5%) were males and 46 (57.5%) were females with an overall mean age of 24.6±3.68 years. Each group had 20 (25%) subjects. All three concentrations of povidone iodine provided significant reduction in postoperative trismus compared to the controls. Trismus was less in Group III and Group IV compared to Group II up to 7 days after surgery.

Conclusion: Irrigation with 3% povidone iodine concentration was found to be more effective in reducing the level of facial swelling after impacted third molar surgery. (ClinicalTrials.gov Identifier: NCT03894722)

Keywords: Maxillofacial surgery, Third molar, Povidone-Iodine, Swelling, Trismus
(JPMA 70: 2304; 2020) DOI: <https://doi.org/10.47391/JPMA.130>

Introduction

The surgical extraction of impacted third molars is one of the most frequently performed procedures in dentoalveolar surgery.^{1,2} As part of the human body's ability to self-heal, characteristic symptoms following third molar extraction, such as pain, swelling or trismus, may commonly appear to respond favourably to the surgical trauma which led to patient discomfort during the post-operative period. Although the risk/benefit analyses are available in literature, there remains some controversy regarding which specific methods best address improvements in patient comfort and the enhancement of well-being in the post-operative period.³

In spite of difficulties in identifying the main aetiology among various predisposing factors, various strategies are associated with third molar surgery.^{4,5} Most studies describe the use of topical antimicrobial agents to stave off any microbial threat during wound-healing.^{6,7} Despite

warnings regarding the misuse and overuse of antibiotics that could raise the risk of developing antimicrobial resistance, there has been a dwindling reliance on antibiotic prophylaxis or pre-emptive antimicrobial medication for surgery to reduce the incidence of inflammatory complications and impaired wound-healing.⁷

Polyvinylpyrrolidone iodine (PVP-I; povidone-iodine), formed following the binding of free iodine to PVP, is a highly potent antiseptic water-soluble agent used for skin preparation before and after surgery. PVP-I shows bactericidal activity against a wide range of microorganisms, including bacteria, fungi, protozoa and viruses. Although PVP does not show any intrinsic antimicrobial activity, its role in free-iodine delivery directly to bacterial target cell membranes has been described. In more recent studies, haemostatic, osteogenic and anti-oedematous effects of PVP-I have been demonstrated with significant results.^{5,6,8,9} Its potent anti-oedematous activity at low concentrations was associated with the inhibition of human inflammatory mediators such as histamine, bradykinin, serotonin prostaglandins, leukotrienes and other substances released into their surroundings by human effector cells immediately after injury.¹⁰

Exercising precautions with patients undergoing impacted third molar surgery in the intra-operative phase may allow

¹Department of Oral and Maxillofacial Surgery, Istanbul Aydın University, Istanbul, Turkey; ²Department of Oral and Maxillofacial Surgery, Eskisehir Osmangazi University, Eskisehir, Turkey; ³Department of Oral and Maxillofacial Surgery, Gungoren Oral And Dental Health Center, Istanbul, Turkey; ⁴Department of Oral and Maxillofacial Surgery, Usak University, Usak, Turkey; ⁵Department of Oral and Maxillofacial Surgery, Biruni University, Istanbul, Turkey.

Correspondence: Esra Yuce. e-mail: dt.esrayuce@gmail.com

for a reduction in the rate of development of post-operative inflammatory complications.¹¹ It was reported that PVP-I had haemostatic and anti-oedematous properties with satisfactory results when used as an irrigation or coolant solution after or during extraction; however, the ideal concentration of PVP-I for maximal efficacy was not clarified.^{5,6,8,11}

The current study was planned to compare the efficacy of different concentrations of PVP-I in the prevention of postoperative swelling and trismus when used as a coolant and irrigation solution during the impacted mandibular third molar surgery.

Patients and Method

The randomised, prospective, double-blind and controlled study was conducted from October 2016 to January 2018 at the Department of Oral and Maxillofacial Surgery, Faculty of Dentistry, Biruni University, Istanbul, Turkey. It comprised individuals who underwent surgical removal of pathology-free completely unerrupted mandibular lower third molars. After approval from the ethics committee of Acibadem University, Istanbul, Turkey, the sample size calculation was done on the basis of $\alpha=5\%$ and power of $=80\%$ using the following formula⁵:

$$N = \frac{(r+1)(Z_{\alpha/2} + Z_{1-\beta})^2 \sigma^2}{rd^2}$$

Those included were aged 18-30 years without systemic diseases, completely unerrupted mandibular lower third molars described as class C/1-3 according to the Pell-Gregory classification.¹² Those excluded were because of pregnancy/lactation, medication usage that could adversely affect the healing process, presence of any condition such as inflammation, periodontitis, dental abscess in the area of the impacted teeth, smoking, undergoing anti-inflammatory or antibiotic drugs therapies <1 week before surgery, history of hypersensitivity to iodine, and any thyroid diseases.

After taking informed consent, the sample was randomised into four equal groups using sequentially-numbered opaque sealed envelopes. Group I was taken as control and was subjected only to saline. Further, 10% PVP-I solution was diluted with saline to obtain an irrigation solution at different concentrations for surgical procedures. Group II was given 0.5% concentration of PVP-I (1ml PVP-I /200 ml saline); Group III had 1% concentration of PVP-I (2ml PVP-I /200ml saline); and Group IV was given 3% concentration of PVP-I (6ml PVP-I /200 ml saline).

In order to standardise the surgical procedure, each patient underwent the same surgical technique by the same

surgeon. Local anaesthesia of the inferior alveolar, lingual and buccal nerves was carried out by using 2% lidocaine with 1:80,000 epinephrine. A full-thickness buccal mucoperiosteal flap was reflected and alveolar bone was removed buccally on the distal aspect of the impacted tooth using a round bur under PVP-I solution or saline irrigation. After single tooth extraction in each patient, irregular bony margins were smoothed and the alveolar socket was irrigated with 10ml PVP-I solution in Groups II, III and IV, and with equal amounts of saline in the control group. The flap was hermetically sutured with 3-0 silk in all groups. Only analgesic ibuprofen 200 mg (1 tablet every 12 hours) and mouth rinse (0.2% chlorhexidine, twice daily) were prescribed for 7 days. No antibiotics or steroids were administered to any of the patient. The patients were followed up post-operatively on days 2 and 7.

Pre-operatively and post-operatively on days 2 and 7 following the surgical procedure, facial measurements were recorded in the closed mouth position. All assessments were done by an attending surgeon blinded to the study in order to reduce bias.

The relationship of mandibular third molar to the ramus of the mandible according to the Pell-Gregory classification¹² was recorded as a clinical variable after the operation. The maximum mouth opening and swelling were evaluated using a digital calliper. The degree of trismus was assessed by measuring the distance between lower and upper incisal borders of the central incisors. For the assessment of swelling, three facial lines were measured on the operated side using several landmarks, such as the external

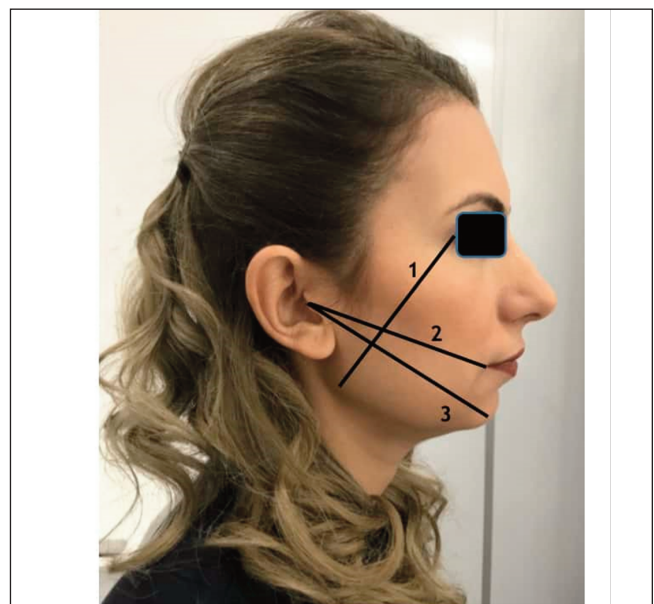


Figure: Linear demarcation measures for swelling: canthus-gnathion line¹; tragus-commissure line²; tragus-pogonion line³.

canthus of the eye, the gonion angle, the lower border of the tragus, soft pogonion, and the mouth commissure (Figure).

Statistical analysis was done using SPSS 22. The 4 groups were compared in terms of baseline descriptive data, including mean age, gender distribution and relation of tooth to the ramus of the mandible by one-way analysis of variance (ANOVA), chi-square and Fisher Freeman Halton test respectively to avoid the interference of confounding variables. Shapiro Wilks test was used to verify the distribution for normality. Inter-group comparisons were analysed with one-way ANOVA and the Tukey honestly significant difference (HSD) test was used to identify which group samples differed significantly from the other groups. For repeated measurements, analysis of variance and Bonferroni's test were performed. P<0.05 was considered significant.

Results

Of the 80 patients, 34(42.5%) were males and 46 (57.5%) were females with an overall mean age of 24.6±3.68 years. Each group had 20(25%) subjects No significant differences in mean age, gender distribution and relation of tooth to the ramus of the mandible were identified among the groups (Table 1).

There was no significant difference between mean pre-

Table-3: Facial swelling was evaluated between groups and within each group preoperatively and on postoperative days 2 and 7. Values are expressed as the mean.

Time	Group 1 Mean±SD	Group 2 Mean±SD	Group 3 Mean±SD	Group 4 Mean±SD	p-value ¹
Tragus-comissure line (cm)					
Preop	11.51±0.73	11.52±0.7	11.67±0.41	11.13±0.44	0.033
Postop. day 2	12.85±0.51	12.49±0.68	12.28±0.48	11.47±0.41	0.001
Postop. day 7	12.22±0.63	12.02±0.71	11.79±0.42	11.16±0.43	0.001
p-value ²	0.001	0.001	0.001	0.001	
Preop-Postop. day 2 p-value ³	0.001	0.001	0.001	0.001	
Preop-Postop. day 7 p-value ³	0.001	0.001	0.001	0.092	
Postop. day 2- day 7 p-value ³	0.001	0.001	0.001	0.001	
Tragus-pogonion line (cm)					
Preop	14.12±1.26	14.23±1.01	14.6±1.01	14.18±0.9	0.469
Postop. day 2	15.82±0.93	15.26±1.02	15.1±1.03	14.36±0.86	0.001
Postop. day 7	15.3±1	14.72±1.07	14.73±1	14.19±0.9	0.009
p-value ²	0.001	0.001	0.001	0.001	
Preop-Postop. day 2 p-value ³	0.001	0.001	0.001	0.001	
Preop-Postop. day 7 p-value ³	0.001	0.001	0.001	0.248	
Postop. day 2- day 7 p-value ³	0.001	0.001	0.001	0.001	
Canthus-gnathion line (cm)					
Preop	9.2±0.71	9.99±0.66	11.01±0.99	9.7±1.19	0.001
Postop. day 2	9.79±0.7	10.4±0.68	11.32±1.02	9.82±1.21	0.001
Postop. day 7	9.51±0.69	10.14±0.67	11.1±0.98	9.7±1.19	0.001
p-value ²	0.001	0.001	0.001	0.001	
Preop-Postop. day 2 p-value ³	0.001	0.001	0.001	0.001	
Preop-Postop. day 7 p-value ³	0.001	0.001	0.018	1	
Postop. day 2- day 7 p-value ³	0.001	0.001	0.001	0.001	

¹One Way ANOVA test; ²Repeated measures analysis of variance; ³Bonferroni Test (p<0,05); SD: Standard deviation.

Table-1: Comparison of baseline descriptive data in 4 groups.

	Group 1	Group 2	Group 3	Group 4	p-value
Age Mean±SD	24.55±3,33	24.75±3,45	24.60±3,92	24.5±4,01	0.997 ¹
Gender n (%)					
Male	10 (50)	7 (35)	9 (45)	8 (40)	0.872 ²
Female	10 (50)	13 (65)	11 (55)	12 (60)	
Relation to Ramus n (%)					
C1	6 (30)	9 (45)	7 (35)	8 (40)	0.952 ³
C2	9 (45)	8 (40)	9 (45)	7 (35)	
C3	5 (25)	3 (15)	4 (20)	5 (25)	

¹Oneway ANOVA Test; ²Chi-square Test; ³Fisher Freeman Halton Test (p<0,05); SD: Standard deviation

Table-2: Mouth opening was evaluated between groups and within each group preoperatively and on postoperative days 2 and 7. Values are expressed as the mean.

Time	Group1 Mean±SD	Group 2 Mean±SD	Group 3 Mean±SD	Group 4 Mean±SD	p-value ¹
Inter-incisal distance (cm)					
Preop	4.38±0.33	4.44±0.42	4.22±0.44	3.97±0.49	0.004
Postop. day 2	2.52±0.37	3.14±0.48	3.5±0.46	3.3±0.44	0.001
Postop. day 7	3.18±0.39	3.86±0.49	4.02±0.42	3.84±0.5	0.001
p-value ²	0.001	0.001	0.001	0.001	
Preop-Postop. day 2 p-value ³	0.001	0.001	0.001	0.001	
Preop-Postop. day 7 p-value ³	0.001	0.001	0.001	0.001	
Postop. day 2- day 7 p-value ³	0.001	0.001	0.001	0.001	

¹One Way ANOVA test; ²Repeated measures analysis of variance; ³Bonferroni Test (p<0,05). SD: Standard deviation

operative interincisal mouth opening measurements among the groups (p>0.05). Trismus was assessed with regard to reduction in the maximum interincisal distance of each patient between the pre-operative period and on post-operative days 2 and 7. There was a significant difference between Group I and the other three groups on postoperative days 2 and 7 (p<0.05). Mouth opening measurements in groups irrigated with PVP-I was greater than the control group (p<0.05). In groups irrigated with PVP-I, the limitation of the mouth opening on average on postoperative days 2 and 7 was less in Group III and Group IV compared to Group II. Although there was no significant difference between Group III and Group IV, the differences between study groups and the control group were statistically significant (Table 2).

Swelling was expressed as the increase in the tragus-commissure, canthus-gnathion and tragus-pogonion lines on postoperative days 2 and 7 compared to the baseline measurements. In all groups, mean facial swelling was significantly increased on postoperative day 2, and a gradual decreasing in swelling was observed from day 2 to day 7. The length of the tragus-commissure line on postoperative days 2 and 7 in Group IV was significantly less than the other groups (p<0.05). Compared to the

intervention groups, the increment in measurements of the tragus–pogonion line on postoperative days 2 and 7 were greater in the control group at each time point ($p < 0.05$). The intervention groups showed considerably better reduction in the increase. Differences between the pre-operative and post-operative values on days 2 and 7 were greater in groups I, II and III, while on the 7th post-operative day, the average score was significantly similar to the pre-operative values in Group IV ($p < 0.05$). Irrigation in Group IV was more effective in reducing the level of facial swelling on postoperative days 2 and 7 after impacted third molar surgery (Table 3).

Discussion

Surgical procedures are routinely followed by an inflammatory process, which is the first line of protective response by a tissue to injury.^{3,13} It is a well-known fact that the intensity of associated pain reaches nearly its maximum for a duration of about 3-5 hours and it may last as long as 2-3 days; and relief may be achieved within 7 days after surgery.^{14,15} Depending on the amount of hard- and/or soft-tissue trauma based on the anatomical position of the third molar, the incidence of swelling peaks 48-72 hours after surgery, and post-operative inflammation can potentially persist with a decreasing trend 5-7 days after surgery.¹⁴ Inflammatory complications are the main cause of increased post-operative patient discomfort and delayed healing process in third molar surgery. Many studies aimed at controlling acute inflammation and/or minimising the infection risk have relied on the efficacy of drugs, such as antibiotics, corticosteroids, non-steroidal anti-inflammatory drugs (NSAIDs), at various stages of surgery or processing dealing with irrigation and removal of debris and organic matter using various disinfectant solutions.^{13,16}

PVP-I is a broad-spectrum and fast-acting antiseptic solution that has been shown to exhibit a wide range of bactericidal, as well as virucidal, fungicidal and protozoicidal activities by rapidly releasing the free iodine that penetrates into, respectively, micro-organisms, cytoplasmic membrane and contents.^{5,8,17} In addition to its antiseptic property, Asimakopoulos et al. reported its anti-oedematous effect as a phenomenon investigated incidentally during the surgical removal of the lower third molar under irrigation with dilute povidone-iodine solution to investigate primarily haemostatic property.¹⁸ The beneficial impact of dilutions from PVP-I stock solutions on preventing post-operative complications is expected, but actual clinical efficacy is unknown.¹⁹ In vitro and in vivo studies have shown that PVP-I could limit the function of the inflammasomes in such a way as to alter prostaglandin synthesis by decreasing leukocyte chemotaxis and its extravasation. It was also shown that the presence of iodine

leads to the destruction of tissue-damaging factors and cytokines, thereby interfering with the inflammatory process and favouring wound-healing.^{4,20,21}

PVP-I solution was selected for this study because it has excellent microbial inhibition and acts as an anti-oedematous agent, has minimal allergic and toxic potential, and enhances osteogenic proliferation and differentiation in an osteoblast-like cell line through the early post-operative period.^{22,23}

Ample research on PVP-I has provided promising evidence regarding its potent chemical properties and biological activities for new applications in many medical fields, including wound-healing, ophthalmological treatment, inhalation therapy for respiratory tract diseases, intra-articular infections, prophylaxis following joint surgery, and allograft transplantation.²¹

A 2011 study determined a significant decrease in the appearance of post-operative swelling when applied PVP-I coolant at a concentration of 0.5 mg/mL in impacted third molar surgery.²⁴ It reported that low concentrations of PVP-I showed an anti-oedematous effect via impeding chemotactic responses of neutrophils activated by leukotriene B4 production. The current study also attempted to investigate the use of povidone-iodine solution using the technique described in literature.²⁴ The PVP-I used here is a commercially available product, which simplifies its use in future clinical applications, making this procedure easy, inexpensive and convenient for both the surgeon and the patient, due to its potential to reduce the overuse of antimicrobial prophylaxis and anti-inflammatory agents after impacted third molar surgery.

Many different methods, including computed tomography (CT) scans, three-dimensional (3D) laser-scanning devices, photographs etc., may be used to assess facial swelling following the dentoalveolar surgery. A study took measurements by marking 4 fixed points (oral commissure, tragus, external canthus, gonion and pogonion,) and 3 surgical baselines to evaluate oedema for the extension of swelling.² To compare oedema, the present study used the anatomical markers described by the earlier study in the closed mouth position for reasons of validity, ease, low cost, and repeatability of the method.²

One study assessed the anti-inflammatory effect of liposomal hydrogel with 3% PVP-I using several established in vitro tests, and found that PVP-I had a beneficial effect on inflammation supported by iodine's free radical scavenging that inhibited mast cell activity and polymorphonuclear neutrophil production of reactive oxygen species.⁴

A study in 2015 compared 0.5mg/mL concentrated solution of PVP-I and saline as a coolant and irrigant during surgical extractions of impacted third molars, and found that PVP-I solution had considerably better efficacy than saline in controlling swelling and trismus, but that there was no significant difference in pain control between the two irrigants.⁵ Pain was not evaluated in the present study as an objective result cannot be obtained when taking into account its subjective nature.

It was reported in many studies that oral-rinsing with PVP-I-hydrogen-peroxide-containing compounds provide an important decrease in bleeding and inflammation in gingivitis patients.²⁵ In 2009, a study performed subgingival irrigation of the periodontal pockets with 10% povidone-iodine solution to gauge the efficacy of basic mechanical periodontal therapy and iodophor solutions as an adjunctive treatment on patients with severe chronic periodontitis, and found improved reduction of gingival inflammation in the regions treated with 10% PVP-I solution irrigation.²⁶

In vivo research using a concentration of 0.5-10% PVP-I solution for antiseptic and anti-inflammatory purposes, including the irrigation of surgical wounds and preparation for surgical interventions, described these dilutions as combining rapid onset, fast acting, high potency, safety and time-saving without serious side effects.^{5,16,21,25} PVP-I solution of 1% concentration was defined as the most viable dilution for wound irrigation by a study;²⁴ however, the ideal concentration of PVP-I for maximal efficacy was not clarified.^{8,17} The antiseptic and anti-inflammatory properties, as well as such potential negative effects of PVP-I as cellular toxicity, depend substantially on the concentration of the solution, which is consequently associated with the concentration of "free" iodine.^{19,22} It also remains unclear as to whether increasing the amount of free iodine by increasing the amount of solvent to concentrated solution will increase the incidence of irritation.^{17,19}

Some studies assessed the toxic effects of dilute concentrations of PVP-I on the survival of pre-osteoblast cells and on cellular differentiation during sterilisation, and on the preservation of allografts, which have demonstrated that alkaline phosphatase activity and osteogenic gene markers were enhanced by appropriate concentrations. It was found that this benefit is inversely proportional to even higher concentrations of PVP-I that include cytotoxicity for epithelial cells, fibroblasts and polymorphonuclear lymphocytes.^{17,22}

Our findings support the notion that PVP-I solution is effective in the management of oedema and trismus when

used as a coolant for the bone drilling in the mandibular lower third molar surgery, while at the same time, variation in the likelihood of inflammatory complications were significantly associated with different concentrations of solution.

The main limitations of the current study was its small sample size which was because of financial and logistical reasons. Further clinical trials with large sample sizes are recommended in order to obtain more definite outcomes and further minimise the undesired post-operative effects on patients.

Conclusion

Irrigation by 3% PVP-I solution had superior efficacy in reducing post-operative trismus, oedema and patient discomfort, and also provided a better opportunity to overcome clinical challenges.

Disclaimer: None.

Conflict of Interests: None.

Sources of Funding: None.

References

1. Tuna A, Delilbasi C, Arslan A, Gurol Y, Tekkanat ZT. Do antibacterial mouthrinses affect bacteraemia in third molar surgery? A pilot study. *Aust Dent J* 2012; 57: 435-9.
2. Antunes AA, Avelar RL, Martins Neto EC, Frota R, Dias E. Effect of two routes of administration of dexamethasone on pain, edema, and trismus in impacted lower third molar surgery. *Oral Maxillofac Surg* 2011; 15: 217-23.
3. Bamgbose BO, Akinwande JA, Adeyemo WL, Ladeinde AL, Arotiba GT, Ogunlewe MO. Effects of co-administered dexamethasone and diclofenac potassium on pain, swelling and trismus following third molar surgery. *Head Face Med* 2005; 1: 11.
4. Beukelman CJ, van den Berg AJ, Hoekstra MJ, Reimer K, Mueller S. Antiinflammatory properties of a liposomal hydrogel with povidone-iodine (Repithel) for wound healing in vitro. *Burns* 2008; 34: 845-55.
5. Hashemi HM, Mohammadi F, Hasheminasab M, Hashemi AM, Zahraei S, Hashemi TM. Effect of Low-Concentration Povidone Iodine on Postoperative Complications After Third Molar Surgery: A Pilot Split-Mouth Study. *J Oral Maxillofac Surg* 2015; 73: 18-21.
6. Kumar BP, Maddi A, Ramesh KV, Baliga MJ, Rao SN, Meenakshi. Is povidone-iodine a hemostyptic? A clinical study. *Int J Oral Maxillofac Surg* 2006; 35: 765-6.
7. The antibiotic alarm. Editorial. *Nature* 2013; 495: 141.
8. Koerner JC, George MJ, Kissam EA, Rosco MG. Povidone-iodine concentration and in vitro killing time of bacterial corneal ulcer isolates. *Digit J Ophthalmol* 2018; 24: 24-6.
9. Jiang Y, Chen L, Zhang S, Tong T, Zhang W, Liu W, et al. Incorporation of bioactive polyvinylpyrrolidone-iodine within bilayered collagen scaffolds enhances the differentiation and subchondral osteogenesis of mesenchymal stem cells. *Acta Biomater* 2013; 9: 8089-98.
10. Chappi DM, Suresh KV, Patil MR, Desai R, Tauro DP, Bharani SKNS, et al. Comparison of clinical efficacy of methylprednisolone and serratiopeptidase for reduction of postoperative sequelae after lower third molar surgery. *J Clin Exp Dent* 2015; 7: e197-202.
11. Laureano Filho JR, Maurette PE, Allais M, Cotinho M, Fernandes C. Clinical comparative study of the effectiveness of two dosages of

- dexamethasone to control postoperative swelling, trismus and pain after the surgical extraction of mandibular impacted third molars. *Med Oral Patol Oral Cir Bucal* 2008; 13: E129-32.
12. Pell GJ, Gregory GT. Impacted mandibular third molars: classification and modified technique for removal. *Dent Dig* 1933;39:330
 13. Rohit S, Praveen Reddy B. Efficacy of postoperative prophylactic antibiotic therapy in third molar surgery. *J Clin Diagn Res* 2014; 8: ZC14-6.
 14. Marković AB, Todorović L. Postoperative analgesia after lower third molar surgery: contribution of the use of long-acting local anesthetics, low-power laser, and diclofenac. *Oral Surg Oral Med Oral Pathol Oral Radiol Endodontol* 2006; 102: e4–e8.
 15. Markovic A, Todorovic L. Effectiveness of dexamethasone and low-power laser in minimizing oedema after third molar surgery: a clinical trial. *Int J Oral Maxillofac Surg* 2007; 36: 226–9.
 16. Al-Khateeb TL, Marouf HA, Mahmud MA. Clinical evaluation of dexamethasone vs. methylprednisolone for reducing postoperative inflammatory sequelae following third molar surgery amongst preschool children in Jeddah, Saudi Arabia; 1996.
 17. Ferguson AW, Scott JA, McGavigan J, Elton RA, McLean J, Schmidt U, et al. Comparison of 5% povidone-iodine solution against 1% povidone-iodine solution in preoperative cataract surgery antisepsis: a prospective randomised double blind study. *Br J Ophthalmol* 2003; 87: 163–7.
 18. Asimakopoulos G, Thompson R, Nourshargh S, Lidington EA, Mason JC, Ratnatunga CP, et al. An anti-inflammatory property of aprotinin detected at the level of leukocyte extravasation. *J Thorac Cardiovasc Surg* 2000; 120: 361–9.
 19. de Jonge SW, Boldingh QJJ, Solomkin JS, Allegranzi B, Egger M, Dellinger EP, et al. Systematic Review and Meta Analysis of Randomized Controlled Trials Evaluating Prophylactic Intra-Operative Wound Irrigation for the Prevention of Surgical Site Infections. *Surg Infect (Larchmt)* 2017; 18: 508-19.
 20. König B, Reimer K, Fleischer W, König W. Effects of Betaisodona1 on parameters of host defense. *Dermatology* 1997; 195(Suppl 2): 42–8.
 21. Kumar KS, Reddy GVK, Naidu G, Pandiarajan R. Role of povidone iodine in periapical surgeries: Hemostyptic and anti-inflammatory? *Ann Maxillofac Surg* 2011; 1: 107-11.
 22. Zhao Y, Hu X, Li Z, Wang F, Xia Y, Hou S, et al. Use of polyvinylpyrrolidone-iodine solution for sterilisation and preservation improves mechanical properties and osteogenesis of allografts. *Sci Rep* 2016; 6: 38669.
 23. Schmidlin PR, Imfeld T, Sahrman P, Tchouboukov A, Weber FE. Effect of shorttime povidone-iodine application on osteoblast proliferation and differentiation. *Open Dent* 2009; 3: 208–12.
 24. Arakeri G, Brennan PA. Povidone-iodine: An anti-oedematous agent? *Int J Oral Maxillofac Surg* 2011;40:173-6.
 25. Ader AW, Paul TL, Reinhardt W, Safran M, Pino S, McArthur W, et al. Effect of mouth rinsing with two polyvinylpyrrolidone-iodine mixtures on iodine absorption and thyroid function. *J Clin Endocrinol Metab* 1998; 66: 632–5.
 26. Kotsilkov K, Emilov D, Popova C. Subgingival Irrigations With Povidoneiodine As adjunctive treatment of chronic periodontitis. *Journal of IMAB - Annual Proceeding (Scientific Papers)* 2009; 2: 84–8.