

## Anatomical variations in upper arm vasculature pertinent to haemodialysis access creation: Are surgeons aware sufficiently?

Zia Ur Rehman,<sup>1</sup> Zainab Majid,<sup>2</sup> Laila Tul Qadar,<sup>3</sup> Aamina Majid<sup>4</sup>

### Abstract

There exist wide anatomical variations of upper limb. Their implication is perhaps greatest when it comes to failure of arteriovenous fistula (AVF) for chronic haemodialysis. Among arteries of forearm, brachial artery is of note, whose high bifurcation is associated with increased risk of failure. The superficial and accessory variants also cause difficulty for the surgeon. The single unpaired brachial vein and stenosis of cephalic vein compound the difficulties associated with AVF among many others. A thorough understanding of surgeons regarding normal anatomy and diverse variants holds high importance in context of deciding an appropriate site for arteriovenous (AV) anastomosis. Negligence in creation of fistula not only pose a threat to patients of end stage renal disease (ESRD) but also contributes to numerous other complications involving nerves and drug administration.

**Keywords:** Brachial artery; basilic vein; arteriovenous fistula; vascular variations.

**DOI:** <https://doi.org/10.47391/JPMA.893>

### Introduction

End stage renal disease (ESRD) is a prevalent and life threatening disorder requiring urgent renal replacement therapy (RRT) with 63% of these RRTs comprising of chronic haemodialysis.<sup>1</sup> An essential component of haemodialysis is creating a suitable vascular access and maintaining its patency. The three types of vascular accesses that are commonly used include arteriovenous fistula (AVF), arteriovenous graft (AVG) and central venous catheter (CVC).<sup>2</sup> The gold standard modality for chronic haemodialysis remains AVF; however, graft is considered in conditions of failure of fistulas, inappropriate vessels or in aged patients with a limited life expectancy of around 2 years.<sup>2,3</sup> The placement of fistulas is done almost six months before initiating dialysis to allow improved

maturation.<sup>1</sup> AVFs are considered as a first choice of intervention because not only do they have better secondary patency rates but also expose patient to reduced chances of infections, thus holding lower mortality incidences at a lower cost in comparison with AVGs.<sup>1,4,5</sup>

According to literature, primary failure of AVF spans a wide range of 7-40%.<sup>4</sup> Among the possibilities contributing to this figure, presence of diverse anatomic variations of upper limb vessels could be one. Here, we have summarized the different routes, origins and other unique variants of vessels commonly used in fistulas for chronic haemodialysis, their outcomes in creation of anastomosis and various other complications observed in daily practice.

### Arteriovenous Fistula

The preferred site of AVF creation is at the wrist or at the elbow as radiocephalic or brachiocephalic fistula, alternate access can be brachiobasilic and brachialbrachial fistula. The anatomy of upper extremity has frequently presented with diverse variations. In a study by Grover et. al, aberrant vasculature was reported in 70% of upper limbs with 9% of these being congenital abnormalities.<sup>6</sup>

Knowledge of anatomical variations is of paramount importance as it helps to decide the vascular access procedure. Many times, a forearm graft is selected before a basilic transposition despite KDOQI guidelines.<sup>7</sup>

### Arterial Variations

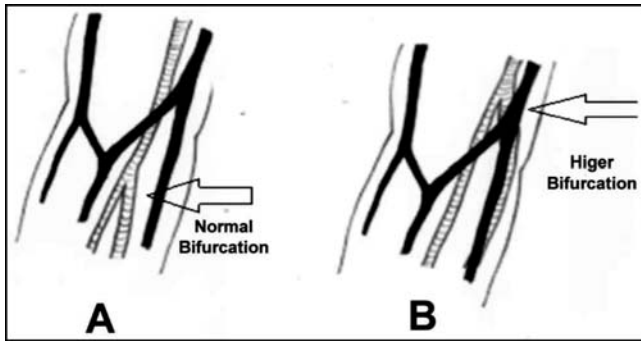
The axillary artery continues as brachial artery and divides into two forearm arteries around elbow: radial and ulnar arteries. These arteries run the forearm musculature.

### Brachial Artery

Brachial artery is continuation of axillary artery and runs its course beyond inferior margin of teres major muscle and up to cubital fossa at elbow, coursing down the forearm as radial and ulnar artery. The usual anatomy of brachial artery also includes median nerve at its lateral aspect. A common anatomical variant, occurring in 20% patients is high brachial artery bifurcation (HBAB) which

<sup>1</sup>Department of Surgery, Aga Khan University Hospital, Karachi <sup>2,3</sup>4th Year MBBS Student, Dow University of Health Sciences, Karachi, <sup>4</sup>Dow University of Health Sciences, Karachi, Pakistan.

**Correspondence:** Zia Ur Rehman. Email: [ziaur.rehman@aku.edu](mailto:ziaur.rehman@aku.edu)



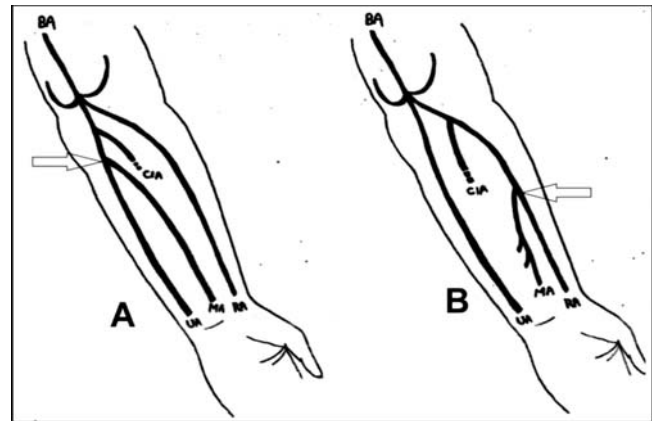
**Figure-1:** Normal (A) and High (B) bifurcation of the brachial artery.

has resulted in increased failure rates of AVF along with reducing its patency.<sup>8</sup> Figure-1 shows the low and high bifurcation of the brachial artery.

Arising from axillary artery and presenting superficially to median nerve is another variant called the superficial brachial artery (SBA). The origination of SBA above ansa medianis accounts for 2-3.5%, making it a rare variant.<sup>9</sup> It becomes significant clinically as SBA can be mistaken for a vein at elbow. This may lead to accidental administration of drugs resulting in possible toxicities and even limb necrosis.<sup>9</sup> Similarly, irregular tortuous routes of SBA can not only be confused for a basilic vein during cannulation but may also become a source of median nerve compression causing an inaccurate diagnosis of carpal tunnel, radiculopathy or pronator teres syndrome.<sup>10</sup> Another important diversity of brachial artery is its duplicate presence, referred to as accessory brachial artery (ABA). This may be a source of uncertainty among the surgeons in context of AVF creation if bifurcation occurs proximally in middle third of arm.<sup>7</sup> According to a study, ABA was found to anastomose with brachial artery in cubital fossa in 11.43% of cases that could impede drug administration and percutaneous catheterization.<sup>10</sup> The superficial route of ABA also makes it vulnerable to injuries that may be followed by bleeding and ischaemia.<sup>10</sup>

### Median Artery

The median artery, originating most commonly from common interosseous artery, usually regresses in post foetal life.<sup>11</sup> However, persistent median artery (PMA) was found in 4% of adults with two main variants, large type (palmar) which is long and reaching up to the palm and second type (antebrachial) terminating prior to reaching the wrist.<sup>8,12</sup> If palmar type is accompanied by a radial artery in proximal or mid forearm, it is not considered a contraindication for radiocephalic AVF.<sup>8</sup> Surgeon's unawareness regarding this extra vessel may result in confusion and hinderance in planning and creating AVF.



**Figure-2:** (A) The median artery is arising from the ulnar artery (UA) below the bifurcation of the common interosseous artery (CIA). (B) In the case presented the median artery (MA) is arising from the radial artery in the mid-forearm.

Also, the clinical importance of PMA is hard to ignore since it has been reported as a cause of carpal tunnel syndrome. This may be due to secondary causes like calcification, thrombosis, atherosclerosis and dilation of PMA.<sup>12</sup> The PMA was also found to compress median nerve and anterior interosseous nerve causing pronator syndrome and anterior interosseous nerve syndrome respectively.<sup>12</sup> Figure-2 illustrates PMA, which can originate from any brachio-antebrachial arterial trunks, including ulnar and radial vessels.

### Radial Artery

Radial artery emerges from brachial artery bifurcation in antecubital fossa coursing distally on anterior part of forearm. After winding through anatomical snuff box, radial artery passes between heads of first dorsal interosseous muscle, accompanied by radial vein along the course. It constitutes deep palmar arch after anastomosis with deep branch of ulnar artery. The radial artery also occurs with a high origin, referred to as brachioradial artery. According to a recent study, brachioradial artery existed in 9.2% of limbs with 82% of them originating from brachial artery and 18% from axillary artery.<sup>13</sup> Presence of high origin has been found to restrict the transradial access, increasing the risk for failure of transradial catheterization.<sup>13</sup>

Another abnormal course of radial artery, lying superficial to tendon of extensor pollicis longus within the anatomical snuffbox, has been observed.<sup>14</sup> The superficial RA lies near cephalic vein that may lead to serious complications including difficulty in IV injection, hindrance in radial pulse palpation and cannulation failure.<sup>14</sup> The superficial radial artery, often confused for cephalic vein, presents with palpation of pulse at an

abnormal location, thus giving a wrong perception of an atherosclerotic lesion. However, this superficial orientation has proven favourable for creation of radio-cephalic fistula with minimal failure rates. Similarly, high chances of success were observed in patients with vessel diameter of more than 2 mm.<sup>15</sup>

### Ulnar Artery

After arising from brachial artery, ulnar artery passes obliquely downwards along ulnar side of the forearm. It usually courses along ulnar border of the wrist crossing the transverse carpal ligament and branching further from superficial and deep volar arches beyond pisiform bone. There is a possible chance of hand ischaemia if ulnar artery with an aberrant route is used for AVF. Rather than adopting a deep route through the muscles, ulnar artery was found to follow a superficial route in 0.7 to 7% of cases.<sup>8</sup> However, despite the risk of ischaemic complication, superficial ulnar artery is not a contraindication and it is recommended to attempt creation of wrist fistula rather than advancing directly towards site of cubital fossa.<sup>16</sup> Inadequate awareness about this variant can result in heavy bleeding if not differentiated from superficial vein and may also cause administration of intra-arterial injections.<sup>17</sup>

A rather rare and unique variant of dual ulnar artery has also been reported. Ulnar artery was also found to have a high origin in the arm known as superficial brachio-ulnar artery, which courses over superficial forearm muscles.<sup>8</sup>

As reported by a series of studies, internal diameter of right and left ulnar artery was reported as 2.4 mm and 2.3 mm respectively, at the site of origin and 2.5 mm and 2.4 mm at the wrist.<sup>18</sup> This broad diameter of ulnar artery makes it a good alternative option for creating AVF and increase their success rate. Therefore, it becomes important for surgeons and anatomist to be well aware of the thickness and diameter variations of ulnar artery to minimize iatrogenic complications and ensure selection of appropriate artery for successful AVF creation.

### Venous Variations

The superficial veins begin in two irregular plexuses, volar venous plexus and dorsal venous network. The plexuses lead to prominent veins of the arms: cephalic, basilic and median antebrachial veins. There are numerous other superficial veins communicating with basilica and forearm accessory veins.<sup>19</sup> The accepted anatomy of upper arm veins involve a pair of brachial veins running parallel to brachial artery and basilic vein, which runs along medial aspect of the arm and then dividing more proximally to join with paired brachial veins near axilla.

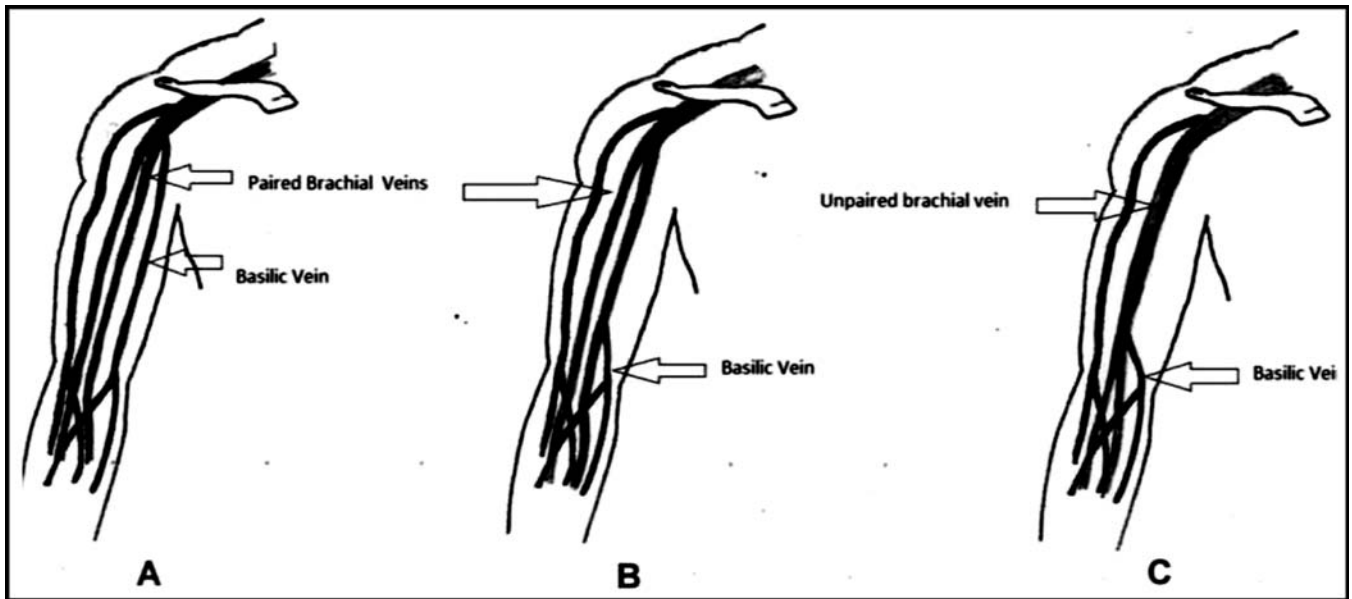
### Brachial Vein

Brachial vein courses deep from anastomosis of radial and ulnar veins and terminates at the inferior border of teres major muscle joining basilic vein to form axillary vein. Its small tributaries drain upper limb muscles like biceps brachii muscle and triceps brachii muscle. In the abnormal anatomy of upper limb veins, incidence of single unpaired brachial vein is 17%. This is affiliated with poor outcomes for secondary AVF.<sup>8</sup> If the brachial vein has been cut off at this location, the effects would be minimal, as remaining fork of brachial vein could accommodate the inflow. Also, brachial vein may seem superficial in lean individuals but is not ideal for dialysis access as it courses close to neurovascular bundle and increases risk of complicated puncture.<sup>8</sup>

### Basilic Vein

Basilic vein originates medially from dorsal venous network of the hand coursing up the forearm connecting to cephalic vein via median cubital vein anterior to cubital fossa. It also perforates brachial fascia during its ascent to medial side of biceps. Despite increasing use of brachio basilic AVF, inadequate anatomical knowledge of basilic vein is available. In traditional text books of anatomy, the usual course is distal basilic vein as lying superficially, ascending along medial aspect of forearm and after crossing the antecubital fossa, veins runs parallel to brachial artery. The paired brachial veins in the deep fascia ascend from forearm to axilla along either side of brachial artery. Anaya-Anyala et al, proposed duplex mapping as an anatomical classification for basilic variations.<sup>20</sup> Javier E et al, in his study described three variants of basilic vein. Type A variant was explained as being similar with usual basilic vein anatomy in which basilic vein joins brachial venous system giving rise to axillary artery in proximal third of upper limb. This variant was found in 66% of arms during vein mapping. In type B variant, anastomosis between basilic vein and brachial venous system occurs in middle or lower third of upper arm. However, at the junction of brachio-basilic vein, basilic vein exists as a pair. This variation accounted for 17% of the cases. Type C variant also had a similar location of brachio-basilic vein junction as in type B but occurred as a single unpaired brachial vein above the confluence with basilic vein. This type also had an occurrence of 17%.<sup>21</sup> Figure-3 shows anatomic classification and distribution of the aforementioned types of basilica vein.

Basilic vein can join a single unpaired brachial vein near elbow, if transposed can lead to entire venous outflow of the upper arm. The basilic vein often forms basilic-brachial junction with paired brachial veins and this route is found to be inappropriate for the formation of AVF.<sup>8</sup>



**Figure-3:** Schematic Illustrations of the anatomic classification of the different variations of basilic veins.

Another variant involves basilic vein coursing as an independent vein and joining axillary vein, prior to joining the cephalic vein. This is a clinically safe variant in which creation of a primary or secondary AVF can be considered as it spares the deep veins of upper arm and allows another attempt for AVF formation.<sup>8</sup>

### Cephalic vein

Cephalic vein is a superficial vein that arises from dorsal venous network of the hand and ascends along anterolateral surface of biceps brachii muscle. At the elbow, it communicates with basilic vein via median cubital vein and at the shoulder passing through deltopectoral triangle, it empties into axillary vein. Various anatomical variations have been described from absent or very thin vein to accessory cephalic vein and occasionally emptying into external jugular vein. However, a research mentioned the following five variants of cephalic vein in their study and their percentage: type A (cephalic-median cephalic vein-44.66%), type B (cephalic-median cubital-median ante brachial-30.1%), type C (single-branched cephalic vein-18.44%), type D (cephalic-median cubital vein-3.88%) and type E (cephalic-median vein-basilic-2.29%).<sup>22</sup> Since cephalic vein is a highly preferable conduit for AVF formation, opting for the most appropriate site and method requires a surgeon's thorough information of these possible variants.

A rare variant terminating at the internal jugular vein has also been reported. Concurrently, a bifid course of terminations on both left and right upper limbs has been described. This vein holds clinical significance as it is used

to achieve central venous access and is suitable for pacemaker and defibrillator implantation.<sup>23</sup> Its utility in haemodialysis is particularly noteworthy as it is employed in the Brescia-Cimino AVF (radiocephalic fistula) at the wrist. Unfortunately it may suffer from cephalic arch stenosis (CAS) with complications presenting as decreased flow, formation of an aneurysm, thrombosis, non-maturation and ending in fistula failure. Cephalic vein transposition (CVT) may be the solution, as illuminated by Jang et al, to be effective and offers well accepted primary and secondary patency rates.<sup>24</sup>

### Multiple interconnecting perforators

The presence of perforating veins, connecting superficial and deep venous systems at elbow, may reduce blood flow to superficial veins and lowering the rate of maturation of AVF.<sup>8</sup> However, presence of this vein may help to maintain patency of fistula while awaiting other interventional procedures.

It is crucial for surgeons to be well aware of normal anatomy of vessels and their distinct variations in context to AV fistula.

### Conclusion

Keeping under consideration, the increasing number of candidates for chronic dialysis, the role of elaborate planning and precise information of anatomic variations needs to be emphasized. Thus, it becomes necessary to meticulously assess the site with scanning techniques and arrangement of regular updating sessions for the surgeons to avoid catastrophic consequences and

improve success rates of AVF.

**Disclaimer:** None to declare.

**Conflict of Interest:** None to declare.

**Funding Disclosure:** None to declare.

## References

1. Bylsma LC, Gage SM, Reichert H, Dahl SLM, Lawson JH. Arteriovenous Fistulae for Haemodialysis: A Systematic Review and Meta-analysis of efficiency and safety outcomes. *Eur J Vasc Endovasc Surg.* 2017; 54:513-22.
2. Allon M. Vascular Access for Hemodialysis Patients: New Data Should Guide Decision Making. *Clin J Am Soc Nephrol.* 2019; 14:954-61.
3. Caro Acevedo P, Marchante R, Thuissard IJ, Sanz-Rosa D, Amann R, Hernandez B, et al. A systematic follow-up protocol achieving a low hemodialysis graft thrombosis rate. *J Vasc Access.* 2019; 20:683-90.
4. Cawich SO, Brown H, Martin A, Newnham MS, Venugopal R, Williams E. Arteriovenous fistulas as vascular access for hemodialysis: The preliminary experience at the University Hospital of the West Indies, Jamaica. *Int J Angiol.* 2009; 18:29-32.
5. Swindlehurst N, Swindlehurst A, Lumgair H, Rebollo Mesa, Mamode N, Cacciola R, et al. Vascular access for hemodialysis in the elderly. *J Vasc Surg* 2011; 53:1039-43.
6. Grover S, Bolisetti S, Sangani S, Gadhavi S, Kulkarni N. Spectrum of vascular abnormalities in color Doppler examination of upper extremities tested for suitability for AV fistula creation in patients of renal failure. *Int J Adv Med.* 2017; 4: 47-50.
7. Kaiser CL, Anaya-Ayala JE, Ismail N, Davies MG, Peden EK. Unrecognized basilic vein variation leading to complication during basilic vein transposition arteriovenous fistula creation: case report and implications for access planning. *Eur J Vasc Endovasc Surg.* 2010; 39:627-9.
8. Kusztal M, Weyde W, Letachowicz K, Golebiowski T, Letachowicz W. Anatomical vascular variations and practical implications for access creation on the upper limb. *J Vasc Access.* 2014; 15:70-5.
9. Troupis T, Michalinos A, Protogerou V, A. Mazarakis, P. Skandalakis. Complex anatomic variation in the brachial region. *Folia morphol.* 2015; 74:118-21.
10. Chakravarthi KK, Siddaraju KS, Venumadhav N, Sharma A, Kumar N. Anatomical variations of brachial artery-its morphology, embryogenesis and clinical implications. *J Clin Diagn Res.* 2014; 8:17-20.
11. Aragão JA, da Silva AC, Anuniação CB, Reis FP. Median artery of the forearm in human fetuses in northeastern Brazil: anatomical study and review of the literature. *Anat Sci Int.* 2017; 92:107-11.
12. Eid N, Ito Y, Shibata MA, Otsuki Y. Persistent median artery: cadaveric study and review of the literature. *Clin Anat.* 2011; 24:627-33.
13. Ha?adaj R, Wysiadecki G, Dudkiewicz Z, Polguy M, Topol M. The High Origin of the Radial Artery (Brachioradial Artery): Its Anatomical Variations, Clinical Significance, and Contribution to the Blood Supply of the Hand. *Biomed Res Int.* 2018/1520929.
14. Nasr AY. The radial artery and its variations: anatomical study and clinical implications. *Folia Morphol (Warsz).* 2012; 71:252-62.
15. Weyde W, Krajewska M, Zmonarski SC, Letachowicz W, Watorek E, Porazko T. et al. The abnormal superficial radial artery does not restrict the successful creation of hemodialysis forearm arteriovenous fistula. *Clin Nephrol.* 2009; 71:584-7.
16. Banasik M, Madziarska K, Weyde W, Kusztal M, Golebiowski T, Zmonarski S, et al. A rare variant route of the ulnar artery does not contraindicate the creation of a fistula in the wrist of a diabetic patient with end-stage renal disease. *Postepy Hig Med Dosw (Online).* 2011; 65:654-7.
17. Sato K, Murakami K, Mimata Y, Kikuchi Y, Oikawa R, Doita M. Superficial Ulnar Artery Crossing Over the Palmaris Longus Tendon at the Wrist in a Cadaver: A Case Report. *J Hand Surg Asian Pac Vol.* 2018; 23:137-9.
18. Al Talalwah WB, Getachew DR. The Clinical Significance of Ulnar Artery Morphology in Artificial Arterial-Venous Fistula for Hemodialysis. *Malays J Med Sci.* 2015; 22:41-7.
19. Krzysztof Letachowicz, Przemysław Szyber, Tomasz Go?biowski, Mariusz Kusztal, Waldemar Letachowicz, Wacław Weyde, et al. Vascular access should be tailored to the patient. *Semin Vasc Surg.* 2016; 29:146-52.
20. Gerrickens MWM, Vaes RHD, Govaert B, Loon MV, Tordoir JHM, Hoek FV, et al. Three Year Patency and Recurrence Rates of Revision Using Distal Inflow with a Venous Interposition Graft for High Flow Brachial Artery Based Arteriovenous Fistula. *Eur J Vasc Endovasc Surg.* 2018; 55:874-81.
21. Anaya-Ayala JE, Younes HK, Kaiser CL, Syed O, Ismail N, Naoum JJ, et al. Prevalence of variant brachial-basilic vein anatomy and implications for vascular access planning. *J Vasc Surg.* 2011; 53:720-4.
22. Alamshah SM. Cephalic vein anatomy in antecubital fossa during the construction of arteriovenous fistula. *Acta Med Iran.* 2004; 42:218-22.
23. Deog-Im KI, Seung-Ho HA. Venous variations in neck region: cephalic vein. *Intern Jour Anat Var.* 2010; 3:208-10.
24. Jang J, Jung H, Cho J, Kim J, Kim HK, Huh S. Central Transposition of the Cephalic Vein in Patients with Brachiocephalic Arteriovenous Fistula and Cephalic Arch Stenosis. *Vasc Specialist Int.* 2014; 30:62-7.