

Comparison of figure of eight and traditional simple wire closure method to prevent dehiscence after sternal closure

Aleezay Asghar¹, Khawaja Muhammad Talha², Muneer Amanullah³, Syed Shahabuddin⁴

Abstract

Objective: To investigate significant differences, if any, between figure-of-eight method and simple wire closure technique in reducing the incidence of infectious and non-infectious sternal dehiscence in patients undergoing sternal closure.

Method: The systematic review was conducted in the Cardiothoracic Surgery Department at Aga Khan University from 1st December 2015 to 13th December 2017. The review was registered with PROSPERO, the International Prospective Register of Systematic Reviews. Pubmed, Cochrane Library (Wiley) and Scopus databases were searched for articles published up to December 13, 2017. The search was limited to randomised control trials, clinical trials, retrospective cohort studies, journal analyses, systematic reviews and meta analyses. Cadaveric or animal studies and articles published in languages other than English were excluded.

Results: Of the 286 articles retrieved, 265(92.6%) were excluded on the basis of study title and abstract. Another 15(5.2%) were excluded for being irrelevant to the topic n hand, and 6(2.1%) formed the final sample. Of them, 4(66.6%) studies showed no significant difference between the two techniques, while 2(33.3%) found figure-of-eight technique to be superior of the two.

Conclusion: There was no significant difference between the figure-of-eight method and the simple wire technique in reducing the risk of dehiscence in patients undergoing sternal closure.

Keywords: Figure-of-eight, Sternal closure, Sternal dehiscence, Simple wire, Surgical wound dehiscence.

(JPMA 70: 2001; 2020) DOI: <https://doi.org/10.5455/JPMA.20135>

Introduction

Median sternotomy is widely acknowledged as a familiar and reliable approach to allow access to thoracic structures, especially the heart and the great vessels in cardiothoracic surgery.¹ However, the procedure may lead to the potential complication of sternal dehiscence with an incidence of about 0.5% to 8.4% worldwide.²⁻⁴ Sternal dehiscence is the process of separation of the bony sternum, and is often accompanied by infection, sternal destruction and mediastinitis which is the infection of the deep soft tissues.⁵ The incidence rate varies from 0.5% to 5% and mortality rate is as high as 40%.⁶ Risk factors for sternal dehiscence include chronic obstructive pulmonary disease (COPD), redo sternotomies, renal failure, diabetes mellitus (DM), long-term immunosuppressive drugs, obesity, concurrent infection and prolonged postoperative respiratory support.⁶

Several methods are employed to carry out sternal closure in cardiothoracic surgery. These include the traditional simple wire method.⁷ In traditional wire closure, the wires are either pushed across each half of the sternum or are wound in a parasternal or a pericostal arrangement to

prevent sternal damage and weakening of the sternal wire.⁸ Those in favour of this technique argue that it is inexpensive and easily learnt.

The figure-of-eight (FO8) suture is also commonly practised for sternal closure following cardiothoracic surgery both as a routine procedure and as a salvage procedure for a failed initial sternal closure.⁸ This method employs the same technique as the simple wire method except that it requires the wires pushed across in a pattern resembling the figure 8 longitudinally along the length of the sternum. Over the years, the efficacy of the two methods has been a matter of debate.

While some studies reported no significant difference between the methods, others showed that FO8 lowers the risk of non-infectious dehiscence⁹ and postoperative sternal dehiscence.¹⁰ Moreover, this technique has been shown to add to the mechanical stability by exerting an oblique traction in modified transverse sternotomy¹¹ and its use in asymmetric loading conditions can decrease the displacement between the two parts of the sternum.¹² There is also proof regarding greater resistance to failure of the FO8 stainless steel cable system under lateral displacement and high cycle count in longitudinal shear loading conditions.¹³ The FO8 method has also been quoted in literature as a superior technique due to its ability of limiting lateral and longitudinal movement at the

^{1,2}Final (5th) Year Medical Student, Aga Khan University, Karachi, Pakistan;

³National Institute of Cardiovascular Diseases, Karachi, Pakistan; ⁴Aga Khan University, Karachi, Pakistan.

Correspondence: Muneer Amanullah. e-mail: muneer.amanullah18@gmail.com

sternum¹⁴ by distributing the stress over a greater area via a pulley effect, allowing easy approximation with less traction force.¹⁵

On the contrary, disadvantages of this technique have also been suggested. One study reports that FO8 may hamper sternal growth in the paediatric population,¹⁵ while another argues that the usage of less wires may actually increase the risk of developing sternal dehiscence.¹⁶

To prevent such postoperative complications, it is vital that appropriate measures are taken and better, safer surgical techniques are employed to reduce the morbidity and mortality associated with post-surgical complications. The current systematic review was planned to explore one of the several possible causative factors responsible for postoperative complications. The aforementioned two techniques were focussed upon since these methods are the most commonly employed techniques in our part of the world.

Methods

The systematic review was conducted in the Cardiothoracic

Surgery Department at Aga Khan University from 1st December 2015 to 13th December 2017. Pubmed, Cochrane Library (Wiley) and Scopus databases were searched for articles published up to December 13, 2017. The search included all age groups, genders and races undergoing median sternotomies, but was limited to randomised control trials (RCTs), clinical trials, retrospective cohort studies, journal analyses, systematic reviews and meta analyses. Cadaveric or animal studies, protocol-only papers, and articles published in languages other than English were excluded.

The initial search used the terms “open heart surgery OR sternotomy OR sutures OR sternal closure OR suture technique OR bone wire OR simple wire technique OR simple wire sutures OR conventional wire OR traditional closure OR surgical wound dehiscence OR mediastinitis OR coronary artery bypass graft OR CABG”

The subsequent search added the term “figure of eight” with the initial search terms.

The review protocol was registered with International Prospective Register of Systematic Reviews, PROSPERO

Table-1: (a-f): Characteristics of studies included in the systematic review. [(a) Article 1].

#	Title, Author	Study Duration	Methodology	Results	Conclusion
1	Figure of eight vs. interrupted sternal wire closure of median sternotomy, Ramzisham AR ¹⁹	Jan 2007 to June 2008 Duration of participation from postoperative day 2 to 3 months post-surgery	Study Design: Prospective RCT Intervention: FO8 vs Interrupted suture technique in adult patients undergoing CABG Outcome: Dehiscence assessed clinically+ radiologically Population size: 195 (98 with FO8 and 97 with interrupted) Inclusion/Exclusion criteria: Redo surgery, additional surgeries, reoperation for bleeding, sternal fractures were excluded	The incidence rate of sternal dehiscence was 8% (7/98 for FO8; 9/97 for simple wire closure, P value=0.294)	No significant difference between the two techniques in preventing sternal dehiscence

Table-1: (a-f): Characteristics of studies included in the systematic review. [(b) Article 2].

#	Title, Author	Study Duration	Methodology	Results	Conclusion
2	Figure of Eight Wire Sternal Closure Technique Can Reduce Post Open Cardiovascular Surgery Chest Re Exploration and Pain Scores in Diabetic Patients with Severe Obesity (Body Mass Index: 35 40), Syed Jalil Mirhoseini ²⁰	February 2010 to March 2013. Follow up till 2 weeks post-surgery	Study Design: Randomized double blind clinical trial Intervention: FO8 vs Simple Wire technique Outcome: sternal dehiscence and pain score Population size: 80 Inclusion criteria: diabetic patients with severe obesity and heart disease undergoing elective off pump CABG Exclusion: history of re operation and sternal fractures Specific Patient characteristics: Mean age 64.7±13.2 years. 63.7% were male	No significant difference between the two techniques in terms of incidence of sternal dehiscence (p-value= 1) and mediastinitis (p-value= 0.8)	No significant difference between the two techniques

(Registration ID: CRD42017056149).¹⁷ Two investigators were responsible for independently reviewing articles. Whenever there was a difference of opinion, the senior author was consulted for expert opinion.

The researchers noted the characteristics of each article selected (Table 1). the risk of bias was assessed both at study and outcome levels from the information available

in the respective article (Table 2). The results obtained in a selected study, like qualitative comparison, percentage incidence of sternal dehiscence and P value for significant difference among the incidences, were also recorded. A schematic representation of the number of articles shortlisted at each stage of the review in accordance with the PRISMA guidelines¹⁸ was compiled simultaneously (Figure).

Table-1: (a-f): Characteristics of studies included in the systematic review. [(c) Article 3].

#	Title, Author	Study Duration	Methodology	Results	Conclusion
3	Figure Of 8 Sternal Closure Vs Simple Interrupted Sternal Closure In Reducing Sternal Dehiscence In Patients With Coronary Artery Bypass Grafting, Sharjeel Abbas ²¹	17th July to 27th Aug 2012	Study Design: Randomized Controlled Trial Intervention: F08 vs simple wire suture Outcome: Sternal wound dehiscence Population: 200 patients undergoing elective CABG. 100 in the F08 group and the other 100 in the simple wire technique group Exclusion: Nonelective or Re-operative CABG Surgery, osteoporosis of sternum, associated cardiac diseases, COPD, chronic cough, high BMI over 30 kg/m ² Patient characteristics: Age group 40-70 years	10 sternal dehiscence cases were reported: 2 from the F08 group and 8 from the simple wire technique group. Five patients were asymptomatic and without infection. Dehiscence was found in elderly, diabetic, overweight patients with increased CPB and Cross clamp times.	F08 is superior to simple wire technique

Table-1: (a-f): Characteristics of studies included in the systematic review. [(d) Article 4].

#	Title, Author	Study Duration	Methodology	Results	Conclusion
4	Comparison of figure of eight and simple wire sternal closure techniques in patients with non microbial sternal dehiscence, Tekümit H ²²	Jan 2002 to Aug 2008 period	Study Design: Retrospective Cohort Study Intervention: F08 vs simple wire technique Outcome: incidence of non-microbial sternal dehiscence Population: 6211 adult patients undergoing cardiac operations through median sternotomy.	90 of the 6211 developed dehiscence. Rates of sternal dehiscence with F08 and simple wire technique were 1.46% and 1.43%, respectively.	No significant difference between the incidence rates of sternal dehiscence for figure of eight and simple wire technique

Table-1: (a-f): Characteristics of studies included in the systematic review. [(e) Article 5].

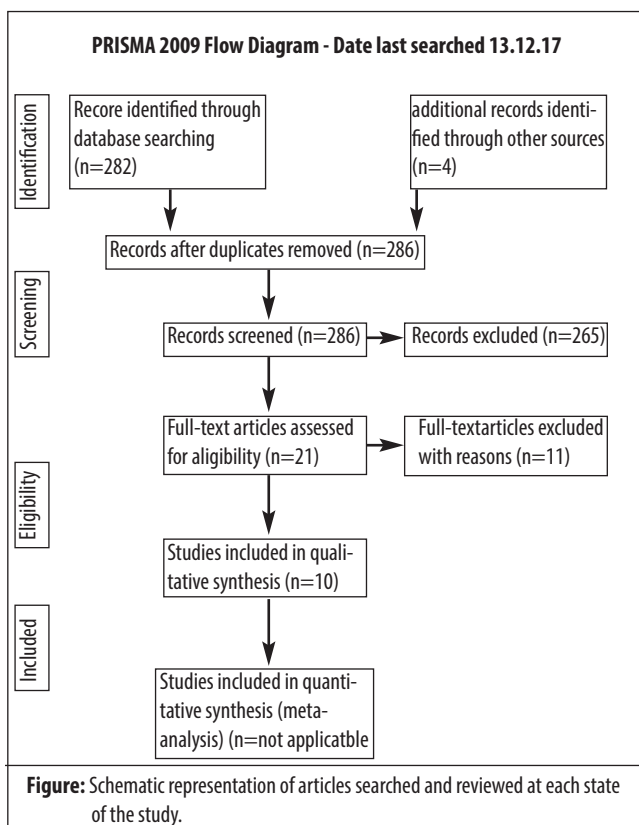
#	Title, Author	Study Duration	Methodology	Results	Conclusion
5	Avoidance of noninfectious sternal dehiscence: figure of 8 wiring is superior to straight wire closure, Sven M SM Alm-dahl ⁹		Study Design: Observational register study Intervention: F08 vs Simple interrupted wire technique Outcome: Non microbial sternal dehiscence Population: 10957 patients, 7835 patients having sternal closure with F08 steel wires and 2122 patients having sternal closure with simple interrupted straight wires	Fourteen patients (0.66%) with single wires and five patients (0.06%) with F08 wires developed non microbial sternal disruption (p < 0.0001).	F08 is superior to simple interrupted wire technique

Table-1: (a-f): Characteristics of studies included in the systematic review. [(f) Article 6].

#	Title, Author	Study Duration	Methodology	Results	Conclusion
6	Is the figure of eight superior to the simple wire technique for closure of the sternum, Noman Khasati ²³	2004	Study design: Best Evidence Topic Intervention: FO8 vs simple wire suture Methodology: 111 articles published in the interval 1966 Aug 2003 were shortlisted out of which 7 were selected	None of articles reviewed demonstrated any superiority of FO8 over simple wiring.	The figure of eight wire technique is not superior to the simple wire technique for closure of the sternum.

Table-2: Risk of Bias for included articles.

#		Random Sequence Generation	Allocation Concealment	Blinding	Risk of Bias		
					Detection Bias	Incomplete Outcome Data	Selective Outcome Reporting
1	Ramzisham Ar et al. ²⁰	Low	Unclear	Unclear	Unclear	Low	Low
2	Syed Jalil Mirhosseini et al. ²¹	Unclear	Unclear	Low	Low	Low	Low
3	Sharjeel Abbas et al. ²¹	Low	Unclear	Unclear	Unclear	Low	Low
4	Tekümit H et al.			Author Did Not Grant Access To Full Article			
5	Almdahl et al. ⁹	High	Unclear	Unclear	Low	Low	Low
6	Casha Ar et al. ²⁵	Not Applicable	Not Applicable	Not Applicable	Low	Low	Low



studies, and 1(16.6%) was a best-evidence topic (BET) study. Of them, 4(66.6%) studies showed no significant difference between the two techniques, while 2(33.3%) found the FO8 technique to be superior of the two methods.

Discussion

There were 3 RCTs that directly compared the two techniques pertinent to the current review. Ramzisham et al. compared the incidence of sternal dehiscence in adult patients undergoing median sternotomy. Sternal dehiscence was assessed clinically as well as through imaging. The incidence rate was reported to be 8% with similar number of patients countering sternal dehiscence for both FO8 and simple wire closure (7/98 for FO8; 9/97 for simple wire closure; p=0.294), deeming the difference statistically non-significant.¹⁹

Mirhosseini et al. conducted a similar study on a population that comprised severely obese diabetic patients using defined parameters. The study included 80 patients, half of whom underwent FO8 closure, while the other half underwent simple wire closure. There was no significant difference between the incidences of sternal dehiscence and mediastinitis in the two groups (p>0.05). However, postoperative pain scores were significantly greater in patients who had simple wire closure compared to FO8 (p<0.05). There was also significantly decreased (p=0.03) need for chest re-exploration after surgery among patients who underwent FO8 closure compared to the simple wire closure. Although the study only comprised diabetic and severely obese individuals, one can argue that these factors

Results

Of the 286 articles retrieved, 265(92.6%) were excluded on the basis of study title and abstract. Another 15(5.2%) were excluded for being irrelevant to the topic in hand, and 6(2.1%) formed the final sample. Among these 6 articles, 3(50%) were RCTs, 2(33.3%) were retrospective cohort

did not interfere with the results since the demographic characteristics of both the groups were similar, thereby nullifying the effect of risk factors such as DM and body mass index (BMI) on the incidence of sternal dehiscence.²⁰

Abbas et al. recently conducted an RCT with 200 individuals undergoing elective CABG. The subjects were equally divided into two groups, and underwent either FO8 or simple wire closure. The authors reported significantly less incidence of sternal dehiscence in FO8 as opposed to simple wire technique (5% total, 2% in FO8 group, and 8% in the simple wire group; $p=0.026$) and recommended the use of FO8 technique as the primary method for sternal closure to reduce the risk of sternal dehiscence. However, the study stated that patients who were not symptomatic for sternal dehiscence were not followed. Therefore, it may be likely that some cases of sternal dehiscence from either group were not reported.²¹

Two retrospective observational studies also directly compared the rates of sternal dehiscence in patients undergoing sternal closure by either of the two techniques. Tekumit et al. conducted a retrospective cohort study on 6211 patients and reported fairly similar incidence rates for both sternal closure techniques: FO8 1.46% versus simple closure 1.43%. There was also no observable difference in mortality rates and postoperative outcomes (time to sternal re-fixation, prolonged intensive care unit [ICU] stay, intra-aortic balloon counter pulsation use, chest re-exploration inotropic agent use and postoperative cerebrovascular accident).²²

In 2013, SM Almdahl et al. conducted a similar study on a sample size of 10957 patients with the number of patients undergoing FO8 (7835) being close to 4 times the number of patients undergoing simple interrupted closure.^{21,22} The difference in the incidence of non-microbial sternal disruption was statistically significant ($p<0.0001$) to conclude the superiority of FO8 over simple wire closure. This study reported a lower incidence of sternal dehiscence in the FO8 group despite the fact that this subgroup had a much larger sample size than that of the simple wire group.⁹

The BET study was conducted by Noman Khasati et al. in 2004. The authors shortlisted 111 articles from Medline, out of which 7 were selected and reviewed. One of them was a direct comparison of a multitude of techniques, including the FO8 and simple wire methods, on sheep models. The other three articles discussed individual techniques (interlocking multi-twisted wire technique, six overlapping FO8 sutures, and inter-locking FO8 technique) and did not include a comparison of the techniques under review; hence, we did not include them in our study. The BET

concluded that the FO8 technique was not superior to the simple wire technique for sternal closure. However, the shortlisted articles included only 4 direct comparisons, and those, too, on experimental models and cadavers, and 3 articles that did not compare the two techniques and discussed different versions of the FO8 or simple wire method.²³

Although we excluded any experimental studies conducted on cadavers, animals or synthetic models in this clinical comparison, we chose to briefly discuss relevant studies to give an overview of all the literature available on this topic.

Losanoff et al. studied multiple sternal wiring methods using cadaveric models to deduce the best method for closure. The researchers studied the mechanical stability of wire closure by application of traction forces on each model. They found that peristernal single wire closure was significantly less mechanically stable than FO8 peristernal and trans-sternal closure. The pericostal FO8 was found to have the highest rate of failure ($p<0.001$).

Experimental studies hold certain advantages over RCTs and animal/cadaveric studies in that the results obtained are reproducible, any bias introduced by structural variability among different subjects is reduced and a more detailed analysis of the various forces, and other parameters acting on the sternum can be obtained all at once.²⁴

Bruhin et al. used computer-based simulations to mimic a human sternum. The stability of the traditional wire closure was tested in comparison to the FO8 technique in both symmetric and asymmetric loading conditions on the sternum. The FO8 technique was shown to substantially decrease longitudinal displacement between the two sternal parts compared to the single loop technique, hence, enhancing stability of the sternum in asymmetric loading conditions.¹²

Dasika et al. conducted a biomechanical analysis using polyurethane foam models as artificial sterna. The experimental study was carried out to primarily determine the stability along the entire length of the sternum using 3 different techniques of sternal closure: 6 simple sternal sutures, 6 FO8 sutures, and 7 simple sternal wire sutures. The FO8 method was not found to be significantly superior to the simple wire technique. In fact, the 7 simple wire technique was better in ensuring lower sternal stability, suggesting that the number of wires is a more important factor in determining sternal stability rather than the technique of the suture.¹

Casha et al. conducted a biomechanical analysis using

metallic sternal models to compare the rigidity of sternotomy fixation using 6 different sternal closure techniques, including the FO8 and simple wire closure methods. The study determined the force exerted during maximum coughing which might cause the sternal wires to untwist, and suggested the use of more wires i.e. 8 simple wires or 4 FO8 wires for sternal closure. However, there was no significant difference between the simple wire technique and FO8 with regards to rigidity of sternal fixation.²⁵

Limitations

The current systematic review is limited to only published literature available online in the English language. Therefore, we recommend further research before one can safely declare the FO8 technique to be superior to the traditional wire technique for preventing sternal dehiscence.

Conclusion

There was no significant difference between the FO8 and the simple wire closure methods in lowering the incidence of sternal dehiscence and other sternal closure-related complications. As such, both these techniques can be used safely for sternal closure, depending on the surgeon's expertise and preference.

Disclaimer: None.

Conflict of Interest: None.

Source of Funding: None.

References

- Dasika UK, Trumble DR, Magovern JA. Lower sternal reinforcement improves the stability of sternal closure. *Ann Thorac Surg* 2003; 75: 1618–21.
- Dickie SR, Dorafshar AH, Song DH. Definitive closure of the infected median sternotomy wound. *Ann Plast Surg* 2006; 56: 680–5.
- Voss B, Bauernschmitt R, Brockmann G, Lange R. Osteosynthetic thoracic stabilization after complete resection of the sternum. *Eur J Cardiothorac Surg* 2007; 32: 391–3.
- Voss B. Sternal reconstruction with titanium plates in complicated sternal dehiscence. *Eur J Cardiothorac Surg* 2008; 34: 139–45.
- Sternal Dehiscence Reconstruction. [Online] [Cited 2020 Feb 29]. Available from: URL: <https://emedicine.medscape.com/article/1278627-overview>
- Aykut K, Celik B, Acikel U. Figure-of-eight versus prophylactic sternal weave closure of median sternotomy in diabetic obese patients undergoing coronary artery bypass grafting. *Ann Thorac Surg* 2011; 92: 638–41.
- Zurbrugg HR, Freestone T, Bauer M, Hetzer R. Reinforcing the conventional sternal closure. *Ann Thorac Surg* 2000; 69: 1957–8.
- Taber RE, Madaras J. Prevention of sternotomy wound disruptions by use of figure-of-eight pericostal sutures. *Ann Thorac Surg* 1969; 8: 367–9.
- Almdahl SM, Halvorsen P, Veel T, Rynning SE. Avoidance of noninfectious sternal dehiscence: figure-of-8 wiring is superior to straight wire closure. *Scand Cardiovasc J* 2013; 47: 247–50.
- Harjula A, Jarvinen A. Postoperative median sternotomy dehiscence. *Scand J Thorac Cardiovasc Surg* 1983; 17: 277–81.
- Costa J, Sonett JR, Ovidio F. Modified transverse thoracosternotomy and cost-effective reinforced sternal closure. *Ann Thorac Surg* 2015; 100: 2376–8.
- Bruhin R. Numerical simulation techniques to study the structural response of the human chest following median sternotomy. *Ann Thorac Surg* 2005; 80: 623–30.
- Wangsgard C, Cohen DJ, Griffin LV. Fatigue testing of three peristernal median sternotomy closure techniques. *J Cardiothorac Surg* 2008; 3: 52.
- Murray KD, Pasque MK. Routine sternal closure using six overlapping figure-of-8 wires. *Ann Thorac Surg* 1997; 64: 1852–4.
- Erdinc M, Ocal A, Ozturk C, Sezer H. Figure-of-eight wiring technique may hamper sternal growth. *Ann Thorac Surg* 1999; 67: 1209–10.
- Alhalawani AM, Towler MR. A review of sternal closure techniques. *J Biomater Appl* 2013; 28: 483–97.
- PROSPERO- International prospective register of systematic reviews. [Online] 2019 [Cited 2019 Nov 7]. Available from: URL: <https://www.crd.york.ac.uk/PROSPERO/>
- PRISMA transparent reporting of systematic reviews and meta-analyses. [Online] 2019 [Cited 2019 Nov 7]. Available from: URL: <http://www.prisma-statement.org/>
- Ramzisham AR, Rafliis AR, Khairulasri MG, Min JOS, Fikri AM, Zamrin MD. Figure-Of-Eight Vs. Interrupted Sternal Wire Closure Of Median Sternotomy. *Asian Cardiovasc Thorac Ann* 2009; 17: 587–91.
- Mirhosseini SJ, Al Saegh SAH, Manshadi SMYM, Naderi N, Hadibarhaghtalab M, Lotfaliani MR. Figure-of-Eight Wire Sternal Closure Technique Can Reduce Post-Open Cardiovascular Surgery Chest Re-Exploration And Pain Scores In Diabetic Patients With Severe Obesity (Body Mass Index) *Int J Clin Exp Med Sci* 2015; 1: 38–41.
- Abbas S, Gul S, Abbas A, Iqbal M, Khan T, Khan JS. Figure-Of-8 Sternal Closure Vs simple interrupted sternal closure in reducing sternal dehiscence in patients with coronary artery bypass grafting (CABG). *Pak Heart J* 2017; 50: 94–9.
- Tekumit H, Cenal AR, Tataroglu C, Uzun K, Akinci E. Comparison of figure-of-eight and simple wire sternal closure techniques in patients with non-microbial sternal dehiscence. *Anadolu Kardiyol Derg* 2009; 9: 411–6.
- Khasati N, Sivaprakasam, Dunning. Is the figure-of-eight superior to the simple wire technique for closure of the sternum?. *Interact Cardiovasc Thorac Surg* 2004; 3: 191–4.
- Losanoff JE, Basson MD, Gruber SA, Huff H, Hsieh F. Single wire versus double wire loops for median sternotomy closure: experimental biomechanical study using a human cadaveric model. *Ann Thorac Surg* 2007; 84: 1288–93.
- Casha AR, Yang L, Kay PH, Saleh M, Cooper GJ. A biomechanical study of median sternotomy closure techniques. *Eur J Cardiothorac Surg* 1999; 15: 365–9.