

## Unsuspected components of a fibroid uterus: Angiolipoleiomyoma

Neha Saleem Paryani<sup>1</sup>, Ruqaiya Shahid<sup>2</sup>

### Abstract

Angiolipoleiomyoma (ALLM) is a rare variant of benign neoplasm of the uterus. It has a prevalence of only 0.06% with only a handful of cases. According to our review of the literature, this case study is one of the only two youngest patients of ALLM reported.

We present the case of a 26-year-old female with ALLM of the uterus. She presented with a large abdomino-pelvic mass and underwent myomectomy and plication of the round ligament to preserve fertility. Although renal angiomyolipomas are more prevalent, extrarenal manifestation especially that which is found in the uterus is still a rare entity. Commonly occurring in women in their fifth to sixth decades of their lives, the case presented here is of a woman in her reproductive age. Therefore, by reporting it we are not only acquainting physicians to consider this as a differential, but also for World Health Organisation (WHO) to include this in their classification of tumours of the female genital tract.

**Keywords:** Angiolipoleiomyoma, uterus, PEComa.

<https://doi.org/10.5455/JPMA.35808>

### Introduction

Leiomyomas are frequently diagnosed in women of reproductive age and are commonly referred to as fibroids of the uterus. Rarely discovered variants include those with abnormal blood vessels (angio-), smooth muscle (myo-), and/or mature adipose tissue (lipo-). Due to the presence of a mixture of tissues this finding can also be referred to as a hamartoma. There are only a handful of cases of Angiolipoleiomyoma (ALLM) of the uterus reported which currently has a prevalence of 0.06% among benign uterine lesions.<sup>1</sup> These benign tumours have a higher incidence in women in their fourth to sixth decades of their lives.<sup>2</sup> The case reported here has an unfamiliar presentation as it was found in a young female. To our knowledge, this is one of the youngest cases found in over 5 years, and after a case of angioleiomyoma was reported in an adolescent girl.<sup>2</sup>

<sup>1</sup>4th year MBBS Student, Dow Medical College, DUHS, Karachi, Pakistan;

<sup>2</sup>Dow Medical College, DUHS, Karachi, Pakistan.

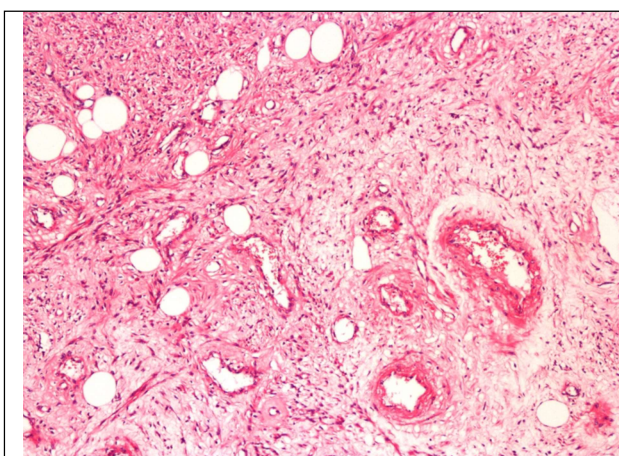
**Correspondence:** Neha Saleem Paryani. e-mail: [nehasparyani@gmail.com](mailto:nehasparyani@gmail.com)

### Case Report

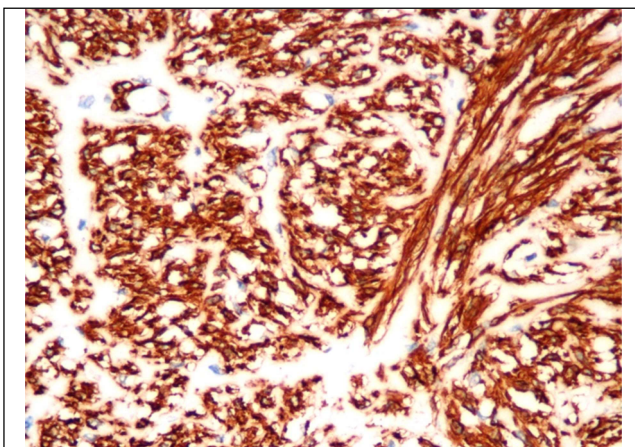
In December 2017, a 26-year-old, married female in her reproductive years, was admitted to the Gynaecology Unit III of the Dr. Ruth K. M. Pfau Civil Hospital, Karachi, with a complaint of a large abdomino-pelvic mass. After taking the history and conducting examinations on the patient, an initial diagnosis of a uterine mass most likely being a fibroid was made. To preserve the fertility given the patient's age, she underwent myomectomy and plication of the round ligament. Intraoperatively, it was observed that there were mild adhesions between the serosa and the rectus sheath. The uterus was 15x15 cm in size with the myoma in the posterior wall extending up to the cervix.

The specimen was sent for histopathological analysis. On gross examination, it comprised of a nodular mass measuring 12x10x8 cm. The cut sections of the tumour revealed a firm, grey white and whorled appearance, amalgamated with a few vessels.

On microscopic examination, a nodular lesion exhibiting variable cellularity of spindle cells admixed with large sized ectatic blood vessels in an oedematous stroma was observed (Figure-1). A small amount of intermixed mature adipose tissue in the form of scattered fat vacuoles was also seen in the lesion. The spindle cells appeared to be smooth muscle cells with eosinophilic cytoplasm and tubular nuclei. Focal clearing of the



**Figure-1:** 10X Angiolipoleiomyoma, showing all three components.



**Figure-2:** 20X Angiomyolipoma positive for Calponin antibody.

cytoplasm was identified as well. Smooth muscle proliferation in the vessel walls and perivascular hyalinisation was further observed. However, mitotic activity was rare. There was no evidence of necrosis and the margins of the lesion were circumscribed and encapsulated revealing no malignant potential of the tumour. The lesion exhibited positivity for Alpha-smooth-muscle-actin Antibody and Calponin Antibody (Figure-2). This pathological examination resulted in a diagnosis of Angiolipoleiomyoma (ALLM).

### Discussion

Over the last two decades, these tumours have been broadly classified as Perivascular Epithelioid cell tumours (PEComas). Tumours included in this group include variants of angiomyolipomas (ALM), lymphangioleiomyomatosis, clear cell/sugar tumour of the lung and myelomelanocytictumor of the falciform ligament.<sup>3</sup> The kidney is an organ where ALMs have been frequently diagnosed having a strong association with tuberous sclerosis.<sup>4</sup> Due to its similarity to renal angiomyolipoma, it is referred to as uterine ALLM, however, it is not associated with tuberous sclerosis.<sup>5</sup>

These tumours present with symptoms like leiomyomas (fibroids) of the uterus. Although usually asymptomatic with just the presence of a pelvic mass, frequent symptoms comprise of menstrual cycle disturbances (menometrorrhagia) and urinary frequency (pressure symptoms) along with mild abdominal pain. These symptoms are highly nonspecific which makes the diagnosis of ALLM challenging based on simple clinical evaluation.

A careful analysis and review of literature exhibited that ALLMs are in the uterine corpus followed by the cervix and the lower segment of the uterus usually as an intramural growth. Sizes of the tumour range from 2-16cm with a median of 8.4 cm.<sup>1,5</sup> Usually the margins of the tumour are circumscribed and encapsulated with no evidence of necrosis, therefore, this is congruent with the case presented. Morphologic features of malignancy are not likely to be present but due to the large size of the tumour mentioned, a clinical follow-up of the patient is advised.

Due to the tumour exhibiting three different components, it is required that blood vessels, adipose tissue and smooth muscle cells are demonstrated for a confirmed diagnosis which can only be found on a histopathological analysis. Therefore, for a definitive diagnosis using a combination of ultrasonography, computerised tomography (CT-scan) and MRI seems unlikely, however, these imaging techniques can indeed provide significant assistance in preoperative evaluation.<sup>1,2,5,6</sup>

### Conclusion

In conclusion, another case registered will add to the insufficient number of reports, aiding in the importance of classifying ALLM as a separate entity. As proposed previously in other reports, ALLM needs to be included in the World Health Organisation's (WHO) Classification of tumours of the Female Genital Tract as a variant of a benign leiomyoma.<sup>7</sup> Inclusion of this tumour will encourage physicians to consider this rarity as an important differential when diagnosing tumours of the female genital tract.

**Consent:** Verbal consent was taken from all patients who presented in the ward and prior to taking any history, examination or reporting of the case.

**Disclaimer:** None.

**Conflict of interest:** None

**Funding disclosure:** None.

### References

1. Cendek BD, Avsar AF, Ergen EB, Yavuz HS, Findik RB. Rarely Seen Benign Tumor of the Uterus, Angiolipoleiomyoma: A Case Report. *Med J Bakirkoy*. 2018; 14:142-5.
2. Sharma C, Sharma M, Chander B, Soni A, Soni PK. Angioleiomyoma uterus in an adolescent girl: a highly unusual presentation. *J Pediatr Adolesc Gynecol*. 2014; 27:e69-71.

3. Yilmaz M, Ingec M, Isaoglu U, Sipal S. Angiomyolipoma of the Uterus. *Eur J Gen Pract.* 2013; 10:178-80.
  4. Coltart TM, Missen GA. A large hamartoma (angioleiomyolipoma) arising from the uterine cervix. *BJOG.* 1975; 82:999-1004.
  5. Ren RL, Wu HH. Pathologic Quiz Case: A 40-Year-Old Woman with an Unusual Uterine Tumor. *Arch Pathol Lab Med.* 2004; 128:e31-2.
  6. Braun HL, Wheelock JB, Amaker BH, Seeds JW. Sonographic evaluation of a uterine angiolipoleiomyoma. *J Clin Ultrasound.* 2002; 30:241-4.
  7. Sahu L, Tempe A, Agrawal A. Angioleiomyoma of uterus. *J Obstet Gynaecol.* 2012; 32:713-4.
-